

Protective Effects of Zingerone on Oxidative Stress in Doxorubicin-Induced Rat Hepatotoxicity

Rezvan Motamedi¹, Soheila Aminzadeh^{1,2}, Mohammad Javad Khodayar^{1,2},
Layasadat Khorsandi³, Maryam Salehcheh*^{1,2}

Abstract

Background: Doxorubicin, a commonly utilized anthracycline antibiotic and chemotherapeutic agent, has been associated with hepatotoxicity as an adverse effect. This study aimed to evaluate protective effects of zingerone, a bioactive compound derived from ginger renowned for its antioxidative attributes, on oxidative stress in doxorubicin-induced rat hepatotoxicity.

Methods: In this experimental study, a total of 48 male Wistar rats were allocated into six distinct groups. The first group received a control treatment of normal saline. The second group was administered an intraperitoneal dose of 20 mg/kg of doxorubicin on day 5. The third group received an oral dose of 40 mg/kg of zingerone for 8 days. The fourth, fifth, and sixth groups were administered zingerone at doses of 10, 20, and 40 mg/kg, respectively, for the same 8-day period. On day 5, all groups, except the control group, received an intraperitoneal injection of doxorubicin. Following a 72-hour interval, the animals were anesthetized, and blood samples were collected to assess serum factors. Moreover, portions of the liver tissue were subjected to histopathological analysis and assessment of oxidative stress parameters.

Results: The activity levels of serum enzymes, including aspartate transaminase (AST), alanine transaminase (ALT), and liver malondialdehyde (MDA), increased in the doxorubicin group. Conversely, the levels of other parameters such as glutathione peroxidase (GPX), superoxide dismutase (SOD), and glutathione (GSH) decreased. However, the co-administration of zingerone effectively reversed these levels, restoring them back to normal.

Conclusion: These findings suggest that zingerone, particularly at a high dose, exhibit a hepatoprotective effect in the doxorubicin-induced hepatotoxicity model.

Keywords: Doxorubicin, Hepatotoxicity, Oxidative stress, Zingerone.

Introduction

Cancer is a chronic disease characterized by uncontrolled cell division, and it ranks among the leading causes of death worldwide. It can occur at any age and has the potential to metastasize and affect the entire body rapidly. While various anticancer medications are available today, they all come with certain side effects (1).

Chemotherapy is a commonly used treatment method for various types of cancer. While its primary goal is to eliminate tumor cells, it can also cause damage to normal cells in the body. One significant form of damage induced by chemotherapy drugs in non-targeted tissues is oxidative stress, which is responsible for drug-related complications (2).

1: Toxicol Research Center, Medical Basic Sciences Research Institute, Ahvaz Jundishapur University of Medical Sciences, Ahvaz, Iran.

2: Department of Toxicol, School of Pharmacy, Ahvaz Jundishapur University of Medical Sciences, Ahvaz, Iran.

3: Cellular and Molecular Research Center, Ahvaz Jundishapur University of Medical Sciences, Ahvaz, Iran.

*Corresponding author: Maryam Salehcheh; Tel: +98 61 33110000; E-mail: salehche-m@ajums.ac.ir.

Received: 30 Nov, 2023; Accepted: 17 Mar, 2024

Doxorubicin, an anthracycline antibiotic, is widely used in tumor chemotherapy for ovarian, bone (3), breast (4, 5), and soft tissue cancers (6). Its mechanism of action involves influencing cellular DNA and inhibiting the topoisomerase II enzyme (7, 8). However, the chemical structure of doxorubicin leads to the induction of oxidative stress and the production of free radicals, resulting in cell damage. Additionally, the disruption of the oxidant-antioxidant systems contributes to tissue damage, leading to lipid peroxidation and protein oxidation. Endogenous antioxidant enzymes such as superoxide dismutase (SOD) and catalase (CAT) play a crucial role in mitigating the effects of reactive oxygen species (ROS) (9, 10).

Doxorubicin has a significant impact on various tissues, including the liver, brain, heart, skeletal muscles, and particularly the kidneys. However, the beneficial effects of doxorubicin are limited due to its severe and chronic side effects, particularly liver congestion (11). The liver, being the largest organ responsible for excretion and metabolism, is susceptible to disorders that are classified as fatal diseases worldwide. Interventions aimed at inhibiting or delaying lipid peroxidation and inflammatory processes through the use of antioxidants show promise in treating liver diseases (1). Proposed strategies to reduce doxorubicin toxicity include optimizing dosage, developing analogues, and combining treatment with antioxidants (12).

Ginger (*Zingiber Officinale*) is a widely used herb and spice known for its traditional medicinal properties such as anti-flatulence, anti-spasm, sudorific, and anti-nausea effects (13). The rhizome of ginger contains oxymethylphenols, including zingerone, zingerole, shaugol, and panadol. Zingerone, a phenolic alkanone, is one of the active compounds in ginger root and has a vanilloid group in its chemical structure. Numerous studies have demonstrated the antioxidant, anticancer, anti-inflammatory, lipolytic, and radio-protective activities of zingerone (11). Its antioxidant effects involve scavenging free

radicals (1) and preventing oxidative stress (14). Additionally, zingerone has shown protective effects in various tissues, such as the kidneys exposed to cisplatin (15) and the liver and kidneys exposed to methotrexate (16). It has also been found to protect the jejunum from cisplatin exposure (17) and mitigate cardiotoxicity induced by carfilzomib (18). Furthermore, zingerone has been shown to increase the intracellular concentration of antioxidant enzymes (4). Based on these findings, this study was designed to investigate the protective efficacy of zingerone against doxorubicin-induced hepatotoxicity in rats.

Materials and Methods

Animal study

The study involved a total of 48 male Wistar rats obtained from the Ahvaz Jundishapur University of Medical Sciences (AJUMS). These rats had an average weight ranging from 170 to 200 g. The animals were housed in a controlled animal facility with a temperature of 23±2 °C, a humidity level of 40-50%, and a 12:12 hour light-dark cycle. They were provided with a diet consisting of hard pellets and had access to tap water. The study protocol was conducted following the guidelines set by the Animal Ethical Committee at AJUMS, with a code of IR.AJUMS.ABHC.REC.1397.008.

Chemicals

Zingerone was obtained from Sigma Aldrich, while the vial of doxorubicin with a dose of 50 mg/25 ml was purchased from EBE We Pharm, Australia. The kits used for the analysis of Glutathione peroxidase (GPX), malondialdehyde (MDA), glutathione (GSH), and superoxide dismutase (SOD) were sourced from Zell Bio, Germany. All chemicals utilized in the study were of analytical grade.

Experimental groups

The study included a total of 48 young male Wistar rats, which were randomly divided into six groups with eight rats in each group. The groups were as following: 1. Control group: Rats received oral administration of water for 8

days and intraperitoneal injection of normal saline (0.9%) on day 5.

2. Doxorubicin group (DOX): Rats received oral administration of water for 8 days and intraperitoneal injection of 20 mg/kg of doxorubicin on day 5.

3. Zingerone group (Zing 40 mg/kg): Rats received oral administration of 40 mg/kg of zingerone for 8 days and intraperitoneal injection of normal saline (0.9%) on day 5.

4. Zingerone 10 mg/kg + doxorubicin group (Zing 10 mg/kg + DOX): Rats received oral administration of 10 mg/kg of zingerone for 8 days and intraperitoneal injection of 20 mg/kg of doxorubicin on day 5.

5. Zingerone 20 mg/kg + doxorubicin group (Zing 20 mg/kg + DOX): Rats received oral administration of 20 mg/kg of zingerone for 8 days and intraperitoneal injection of 20 mg/kg of doxorubicin on day 5.

6. Zingerone 40 mg/kg + doxorubicin group (Zing 40 mg/kg + DOX): Rats received oral administration of 40 mg/kg of zingerone for 8 days and intraperitoneal injection of 20 mg/kg of doxorubicin on day 5.

Serum and tissue sample preparation

For the anesthesia of the animals, a combination of xylazine (9 mg/kg) and ketamine (90 mg/kg) (Alfasan, Netherlands) was administered. After 72 hours of doxorubicin administration, the abdominal cavity was opened, and blood samples were collected in heparin-free test tubes. These samples were then subjected to centrifugation at 2500 rpm for 15 minutes to obtain serum. The serum was used for the analysis of serum factors, specifically AST (aspartate aminotransferase) and ALT (alanine aminotransferase).

The liver was removed and weighed. A portion of the liver tissue was separated and homogenized with PBS (pH=7.4). Subsequently, the homogenized tissue was centrifuged for 10 minutes at 12000 rpm. The resulting supernatant was stored in Eppendorf tubes at -70 °C and later utilized for the measurement of tissue factors, including GSH,

MDA, GPX, and SOD. Another portion of the liver was preserved in a 10% formalin solution at pH=7.4 for subsequent histological and pathological examinations.

Measurement of serum and tissue biomarkers

The levels of MDA and GSH, as well as the activities of SOD and GPX, were determined using commercially available kits (Zell Bio Company) following the instructions provided by the manufacturer.

Histopathological changes

Following blood collection, the livers of the rats were promptly dissected and fixed in a 10% formalin solution. The liver tissues were then dehydrated using a series of alcohol dilutions, embedded in paraffin, and sectioned into 4-6-micron sections. Hematoxylin-eosin (H&E) staining method was employed to stain the sections. For each animal, a total of 6 slides were prepared to examine histological alterations, such as red blood cell congestion and inflammatory cell infiltration. The severity of histological changes was graded on a scale of 0 (no change), 1 (weak), 2 (moderate), and 3 (intense), based on the average values obtained from measurements. Six fields were assessed on each slide, and the mean values were determined while ensuring observer blindness.

Statistical analysis

The mean values of each rat group were calculated and presented as mean \pm SEM (standard error of the mean). To determine the differences between the means and the significance of these differences, an ANOVA test was performed followed by Tukey's Post hoc test. The significance level was set at $p < 0.05$. This analysis was conducted to ensure the significance of the differences observed in the means. The statistical package program Prism 5.0 (San Diego, CA, USA) was utilized for data visualization and chart plotting.

Ethical approval

All methods employed in this study were conducted in compliance with the ethical standards set by the Ahvaz Jundishapur

University of Medical Sciences, Ahvaz, Iran (IR.AJUMS.ABHC.REC.1397.008).

Results

Body weight change and relative weight of liver

In the investigation of zingerone's effects on body weight changes and relative liver weight in doxorubicin-treated rats, the DOX group demonstrated a significant decrease in body weight (-18.14 ± 1.85), compared to the control group ($P < 0.001$). Furthermore, the Zing 20

mg/kg + DOX and Zing 40 mg/kg + DOX groups exhibited notable differences in body weight changes when compared to the DOX-treated rats ($P < 0.05$ and $P < 0.01$, respectively) (Table 1). These results suggest that zingerone may have a potential influence on weight alterations in rats with doxorubicin-induced hepatotoxicity. However, there were no significant distinctions observed among the groups concerning relative liver weight ($P > 0.05$) (Fig. 1).

Table 1. Body weight and liver changes.

Groups	Body weight change (%): $\left(\frac{W_2 - W_1}{W_1}\right) \times 100$
Control	9.58 ± 1.51
DOX	$-18.14 \pm 1.85^{***}$
Zing 40 mg/kg	13.54 ± 0.94
Zing 10 mg/kg + DOX	-20.33 ± 0.74
Zing 20 mg/kg + DOX	$-10.68 \pm 1.97^{\#}$
Zing 40 mg/kg + DOX	$-9.76 \pm 1.44^{##}$

Results are presented as mean \pm SEM. *** ($P < 0.001$) indicates a significant difference compared to the control group. ## ($P < 0.01$) and # ($P < 0.05$) significant differences compared to the DOX-treated rats.

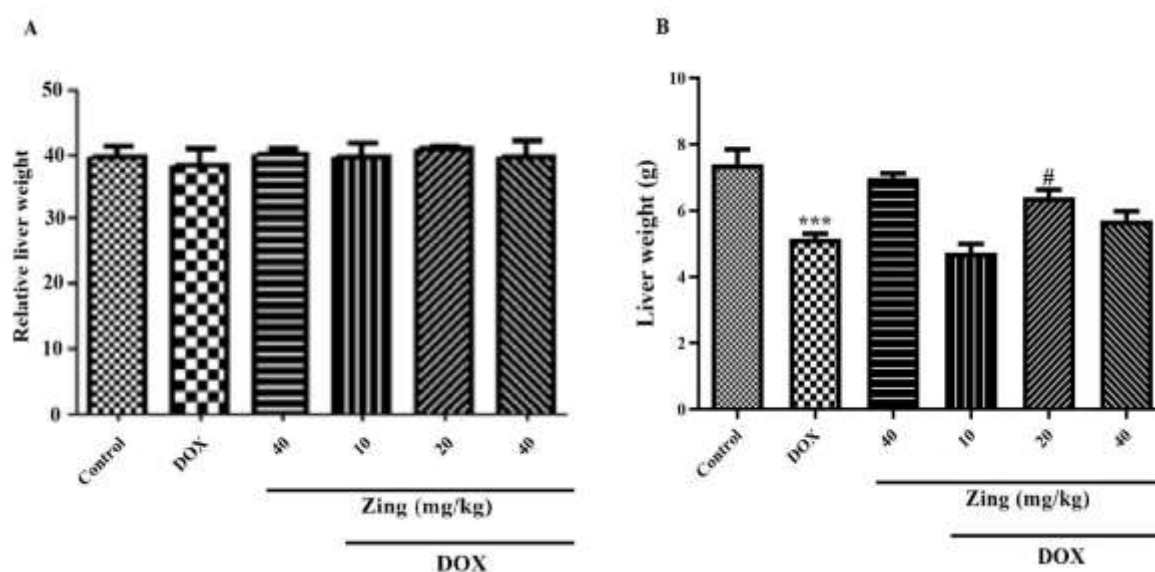


Fig. 1. Effect of zingerone (Zing) and doxorubicin (DOX) on relative liver weight (A) and liver weight (B). (***, $P < 0.001$) indicate a significant difference compared to the control group. (#, $P < 0.05$) signifies a significant difference compared to the DOX-treated rats.

Serum factors

AST

The doxorubicin group exhibited a significantly higher serum AST level than the control group ($P < 0.05$). In the Zing 40 mg/kg

+ DOX group, the serum AST level was significantly reduced by zingerone ($P < 0.05$) when compared to the doxorubicin group (Fig. 2A).

ALT

The doxorubicin group exhibited significantly higher serum ALT levels than the control group ($P < 0.001$). In the Zing 20 mg/kg + DOX and Zing 40 mg/kg + DOX groups,

zingerone, Significantly, reduced the serum ALT level ($P < 0.01$ and $P < 0.001$, respectively) when compared to the doxorubicin group (Fig. 2B).

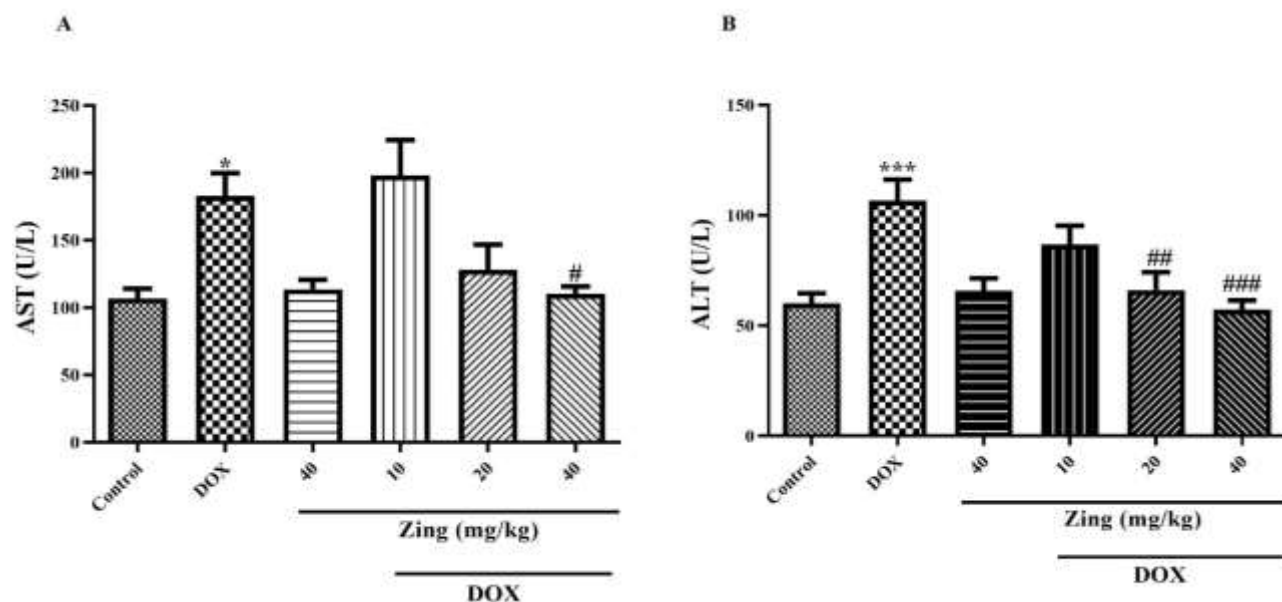


Fig. 2. The effect of zingerone and doxorubicin on serum AST (A) and ALT (B) levels in rats. The data are presented as mean \pm SEM. * ($P < 0.05$) and *** ($P < 0.001$), significantly different over control group. # ($P < 0.05$), ## ($p < 0.01$), and ### ($p < 0.001$) significantly different over DOX treated rats.

Oxidative stress evaluation**The level of MDA in the liver samples**

The doxorubicin group exhibited a significant increase in the MDA level compared to the control group ($P < 0.05$). In the Zing 40 mg/kg + DOX group, the MDA level was significantly decreased by zingerone compared to the doxorubicin group ($P < 0.01$) (Fig. 3A).

The level of GSH in the liver samples

The doxorubicin group demonstrated a significant decrease in the GSH level compared to the control group ($P < 0.05$). In the Zing 40 mg/kg + DOX, the GSH level was significantly increased by zingerone compared to the doxorubicin group ($P < 0.05$) (Fig. 3B).

The activity of liver enzymes

The doxorubicin group demonstrated a significant decrease in the activity of GPX and SOD enzymes compared to the control group ($P < 0.05$). In the Zing 10 mg/kg + DOX, Zing 20 mg/kg + DOX, and Zing 40 mg/kg + DOX groups, the activity of GPX enzyme was significantly increased by zingerone compared to the doxorubicin group ($P < 0.05$, $P < 0.05$, and $P < 0.01$, respectively). Additionally, in the Zing 40 mg/kg + DOX group, the activity of SOD enzyme was significantly increased by zingerone compared to the doxorubicin groups ($P < 0.05$) (Fig. 4).

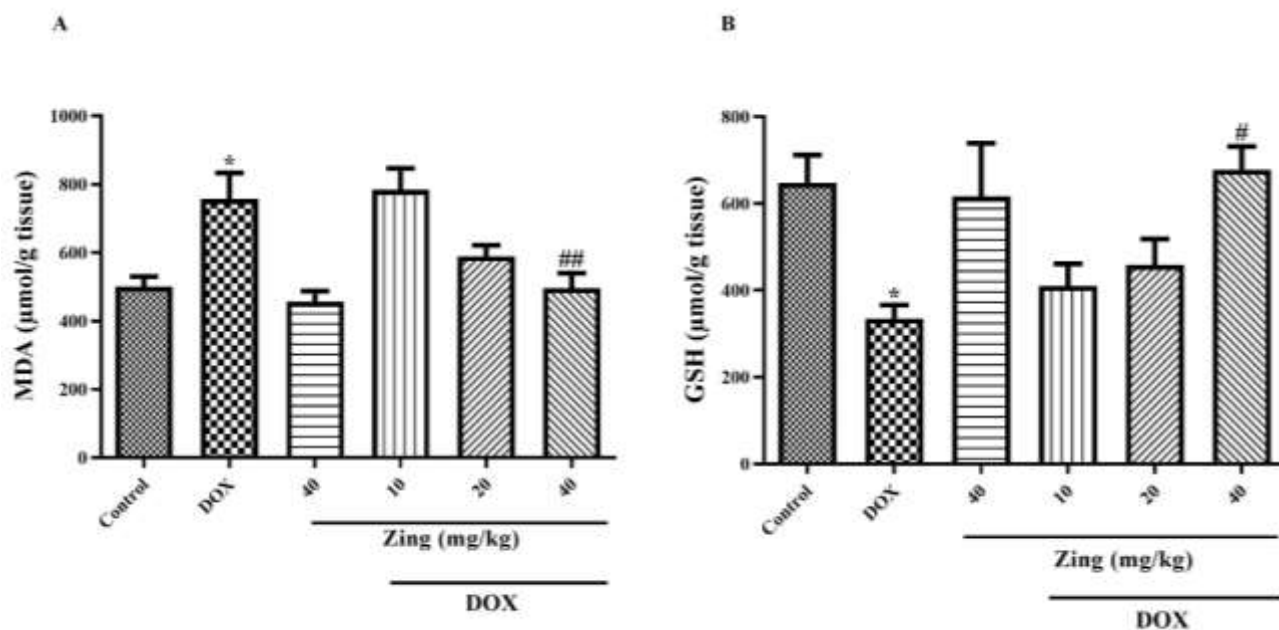


Fig. 3. Effect of zingerone and doxorubicin on the levels of MDA (A) and GSH (B). The data are presented as mean \pm SEM. * $P < 0.05$ indicate statistical significance over the control group. # $P < 0.05$ and ## $P < 0.01$ indicate statistical significance over the doxorubicin-treated rats.

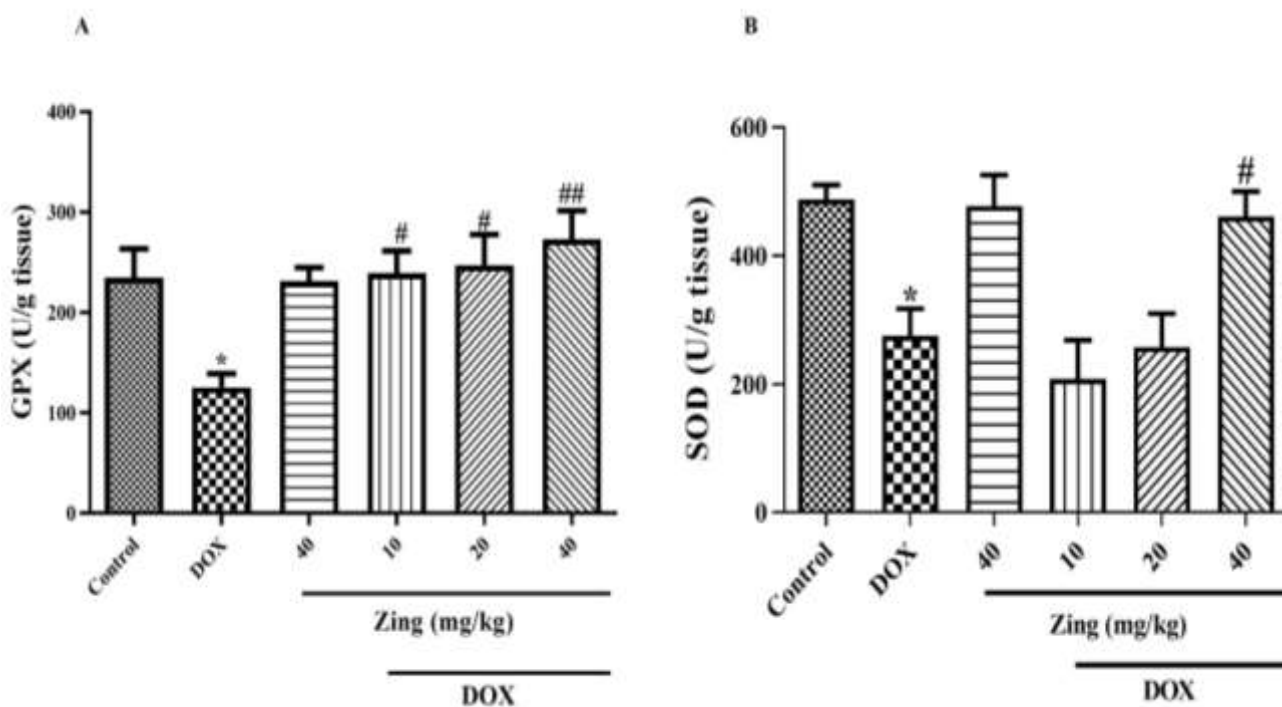


Fig. 4. Effect of zingerone and doxorubicin on the activities of GPX (A) and SOD (B). The data are presented as mean \pm SEM. * $P < 0.05$ statistical significance over the control group. # $P < 0.05$ and ## $P < 0.01$ statistical significance over the DOX group.

Histopathological examinations

All liver sections in both control and zingerone (Zing 40 mg/kg) groups exhibited a normal appearance. However, administration of doxorubicin significantly increased inflammatory cell infiltration and congestion of red blood cells (RBCs) compared to the control group (P<0.001). The combination of lower doses of zingerone with doxorubicin

(Zing 10 mg/kg + DOX) resulted in a slight reduction in RBC congestion and inflammatory cell infiltration. In contrast, co-administration of doxorubicin with higher doses of zingerone (Zing 20 mg/kg + DOX and Zing 40 mg/kg + DOX) significantly reduced RBC congestion and inflammatory cell infiltration compared to the doxorubicin group (P<0.05) (Fig. 5 and Table 2).

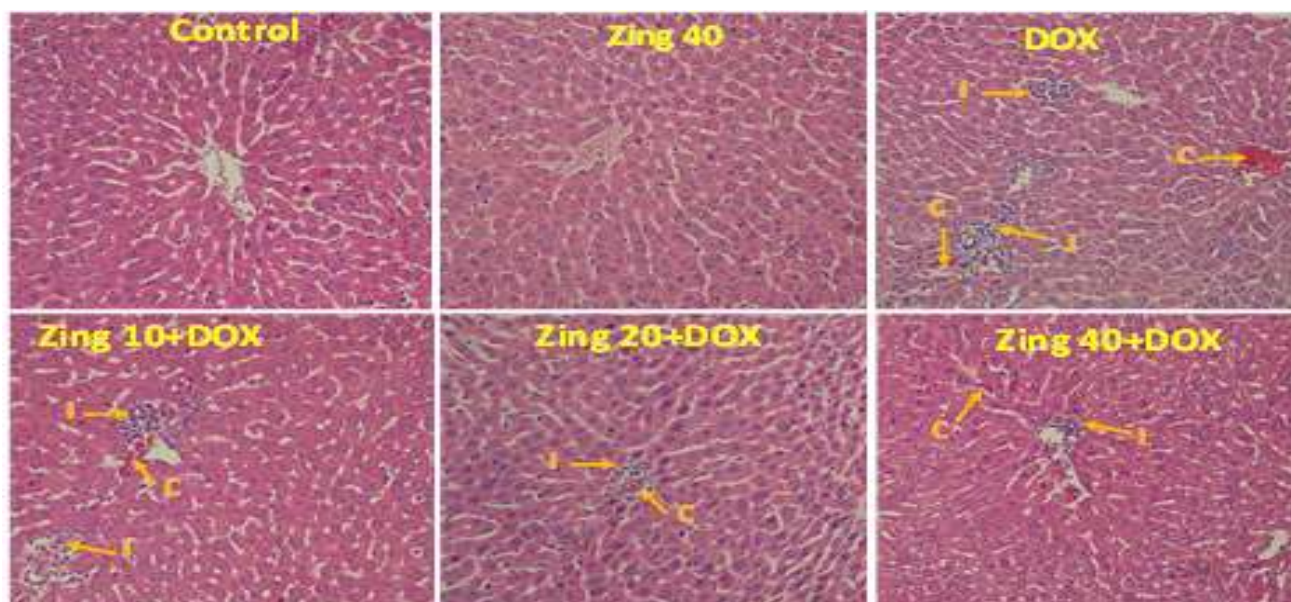


Fig. 5. Light microscopy of cross sections of H&E stained liver from the experimental groups. C: congestion of red blood cells (RBCs); I: infiltration of inflammatory cells.

Table 2. Histological evaluation of liver tissue in rat with doxorubicin-induced hepatotoxicity

Histological criteria	Groups					
	Control	DOX	Zing (40 mg/kg)	Zing (10 mg/kg) +DOX	Zing (20 mg/kg) +DOX	Zing (40 mg/kg) +DOX
Congestion of RBC	0.09 ± 0.00	1.7 ± 0.23***	0.05 ± 0.00	1.5 ± 0.31	0.83 ± 0.15#	0.68 ± 0.24#
Infiltration of inflammatory cells	0.04 ± 0.00	1.3 ± 0.36***	0.01 ± 0.00	1.1 ± 0.18	0.71 ± 0.21#	0.56 ± 0.19#

The data are presented as mean ± SEM, ***P<0.001 significant differences over the control group. #P < 0.05 significant differences over the DOX group.

Discussion

The findings of this study suggest that zingerone, particularly at high doses (Zing 20 mg/kg + DOX and Zing 40 mg/kg + DOX), exhibits a hepatoprotective effect in a doxorubicin-induced hepatotoxicity model. Doxorubicin is a chemotherapy drug that has adverse effects on normal cells (4). However,

its usage is limited due to severe and chronic complications, especially liver damage associated with high drug dosages, which can lead to liver congestion (9). Previous studies have shown that doxorubicin induces inflammatory processes, free radical generation, and lipid peroxidation, resulting in

liver damage (19). Therefore, compounds with antioxidant and anti-inflammatory effects have gained considerable interest. In this study, we investigated the impact of zingerone administration on doxorubicin-induced hepatotoxicity to evaluate the potential moderating role of zingerone on oxidative stress.

Zingerone, a potent antioxidant commonly used as a spice worldwide, has been recognized for its medicinal properties in traditional medicine. Its rhizome contains various compounds, including zingerone, zingerole, and other oxymethylphenols. Numerous studies have reported on the diverse medicinal effects of zingerone, such as its antioxidant, anticancer, anti-inflammatory, lipolytic, and radio-protective properties (11). For instance, Mani et al. (2016) demonstrated that oral administration of zingerole at a dose of 40 mg/kg exhibited antioxidant and anti-inflammatory effects and reduced ethanol-induced hepatotoxicity (11). Similarly, Sarbaz et al. (2013) found that ginger extract displayed corrective effects against hepatotoxicity and renal toxicity induced by Cadmium Bromide (20). Additionally, Newairy et al. (2009) revealed that zingerone, administered at different doses (100-200-300 mg/kg BW), mitigated hepatotoxicity caused by Brome Benzene (460 mg/kg) (21). The results of our study are consistent with the previous studies mentioned. We found that zingerone demonstrated a hepatoprotective effect in the doxorubicin-induced hepatotoxicity model, aligning with the reported antioxidant and anti-inflammatory properties of zingerone (11). This suggests that zingerone has the potential to mitigate liver damage caused by doxorubicin, similar to its effects in other hepatotoxicity models (20, 21). The findings from our study further support the existing evidence on the beneficial effects of zingerone in protecting against liver injury.

The impact of doxorubicin on liver enzymes, such as AST and ALT, has been well-documented (22-24). It is known to cause severe liver damage by inhibiting apoptosis and surpassing caspase III (25). In this study,

the serum concentrations of AST and ALT were significantly elevated in the doxorubicin group compared to the control group. However, when zingerone (40 mg/kg) was administered, there was a decrease in the serum concentrations of AST and ALT compared to the doxorubicin group.

Previous research has shown that doxorubicin increases the level of MDA and damages the lysosome membrane in liver tissue (23). It also depletes the resources of GSH (26) and reduces the activity level of antioxidant enzymes like GPX (27) and SOD (28) in heart tissue. Conversely, studies on kidney tissues have demonstrated that zingerone inhibits lipid peroxidation, prevents the reduction in GSH, and impedes the reduction in antioxidant enzymes (29).

In this current study, the doxorubicin group exhibited a significant increase in MDA level and a decrease in GSH level compared to the control group. The activity levels of liver GPX and SOD enzymes were also significantly reduced in the doxorubicin group. However, when zingerone was administered, there was a significant reduction in lipid peroxidation (MDA) compared to the doxorubicin group. Additionally, zingerone prevented the reduction in GSH level and decreased GPX and SOD activity compared to the doxorubicin group. Numerous studies have reported that doxorubicin causes degeneration of liver cells and severe damage to liver and kidney tissue structure (14, 24). The histopathological findings in this study supported these biochemical observations. Notably, the administration of zingerone significantly improved the histopathological conditions of the liver compared to the doxorubicin group.

In conclusion, our study highlights the significant contribution of oxidative stress in doxorubicin-induced hepatotoxicity. Given the limitations imposed by side effects and hepatotoxicity, the use of antioxidants and liver protective agents could be an effective strategy to mitigate complications associated with doxorubicin intake.

Our results demonstrate that zingerone, through its antioxidant properties, effectively

prevents doxorubicin-induced hepatotoxicity in male Wistar rats in a dose-dependent manner. Further studies are necessary to validate these findings and draw definitive conclusions, but it appears that zingerone may hold promise as an adjunct therapy with anticancer drugs such as doxorubicin.

Acknowledgements

The authors thank the Ahvaz Jundishapur University of Medical Sciences, Ahvaz, Iran, for financially supporting this project. This paper's financial situation was supported by the Pharm. D doctoral thesis of Rezvan Motamedi (grant number: TRC-9708).

Funding

This study was funded by Ahvaz Jundishapur University of Medical Sciences (Ahvaz, Iran) by grant Number of TRC-9708.

References

1. Ahmad B, Rehman MU, Amin I, Arif A, Rasool S, Bhat SA, et al. A Review on Pharmacological Properties of Zingerone (4-(4-Hydroxy-3-methoxyphenyl)-2-butanone). *Sci World J.* 2015;2015:816364.
2. Pieniążek A, Czepas J, Piasecka-Zelga J, Gwoździński K, Koceva-Chyła A. Oxidative stress induced in rat liver by anticancer drugs doxorubicin, paclitaxel and docetaxel. *Adv Med Sci* 2013;58(1):104-11.
3. Shan K, Lincoff AM, Young JB. Anthracycline-induced cardiotoxicity. *Ann Intern Med.* 1996;125(1):47-58.
4. Zhou S, Palmeira CM, Wallace KB. Doxorubicin-induced persistent oxidative stress to cardiac myocytes. *Toxicol Lett.* 2001;121(3):151-7.
5. Zahedian S, Hekmat A, Tackallou SH, Ghoranneviss M. The Impacts of Prepared Plasma-Activated Medium (PAM) Combined with Doxorubicin on the Viability of MCF-7 Breast Cancer Cells: A New Cancer Treatment Strategy. *Rep Biochem Mol Biol.* 2022;10(4):640-652.

Data Availability

Upon reasonable request, the data used and the statistical tests performed in this study will be available from the corresponding author.

Declarations

Ethics approval and consent to participate

All the methods and medicines used for animals have been reviewed and approved by the ethics committee in working with animals of Ahvaz Jundishapur University of Medical Sciences and received the code of ethics (IR.AJUMS.ABHC.REC.1397.008).

Conflict of interest

The authors declare that they have no known competing financial interests or personal relationships that could have appeared to influence the work reported in this paper.

6. Quiles JL, Huertas JR, Battino M, Mataix J, Ramírez-Tortosa MC. Antioxidant nutrients and adriamycin toxicity. *Toxicol.* 2002;180(1):79-95.
7. Minotti G, Menna P, Salvatorelli E, Cairo G, Gianni L. Anthracyclines: molecular advances and pharmacologic developments in antitumor activity and cardiotoxicity. *Pharmacol Rev.* 2004;56(2):185-229.
8. Ghotaslou A, Samii A, Boustani H, Kiani Ghalesardi O, Shahidi M. AMG-232, a New Inhibitor of MDM-2, Enhance Doxorubicin Efficiency in Pre-B Acute Lymphoblastic Leukemia Cells. *Rep Biochem Mol Biol.* 2022;11(1):111-124.
9. Injac R, Perse M, Obermajer N, Djordjevic-Milic V, Prijatelj M, Djordjevic A, et al. Potential hepatoprotective effects of fullereneol C60(OH)24 in doxorubicin-induced hepatotoxicity in rats with mammary carcinomas. *Biomaterials.* 2008;29(24-25):3451-60.
10. Aminzadeh S, Salehcheh M, Khodayar MJ, Goudarzi G, Hemmati AA, Khorsandi LS,

Asgharipour Dasht Bozorg N. The Impact of Metformin on Dust-Induced Histopathological Changes and Oxidative Stress in the Liver: An Insight into Dust Concentration and Liver Biomarkers in Animal Models. *Rep Biochem Mol Biol.* 2023;12(2):306-317.

11. Mani V, Arivalagan S, Siddique AI, Namasivayam N. Antioxidant and anti-inflammatory role of zingerone in ethanol-induced hepatotoxicity. *Mol Cell Biochem.* 2016;421(1-2):169-81.

12. Rastogi RP, Mehrotra BN, Sinha S, Pant P, Seth R. *Compendium of Indian Medicinal Plants. Drug Research Perspectives: New Delhi Publication.* 1994;10:395-8.

13. Pulla Reddy AC, Lokesh B. Studies on spice principles as antioxidants in the inhibition of lipid peroxidation of rat liver microsomes. *Mol Cell Biochem.* 1992;111:117-24.

14. Reddy AC, Lokesh BR. Studies on spice principles as antioxidants in the inhibition of lipid peroxidation of rat liver microsomes. *Mol Cell Biochem.* 1992;111(1-2):117-24.

15. Alibakhshi T, Khodayar MJ, Khorsandi L, Rashno M, Zeidooni L. Protective effects of zingerone on oxidative stress and inflammation in cisplatin-induced rat nephrotoxicity. *Biomed Pharmacother.* 2018;105:225-232.

16. Türk E, Güvenç M, Cellat M, Uyar A, Kuzu M, Ağgül AG, Kırbuş A. Zingerone protects liver and kidney tissues by preventing oxidative stress, inflammation, and apoptosis in methotrexate-treated rats. *Drug Chem Toxicol.* 2022;45(3):1054-1065.

17. Rehman MU, Mir AB, Arif A, Rasool S, Wali FA, Razzaq R, et al. Zingerone protects against cisplatin-induced oxidative damage in the jejunum of Wistar rats. *Orient Pharm Exp Med.* 2015;15:199-206.

18. Alam MF, Hijri SI, Alshahrani S, Alqahtani SS, Jali AM, Ahmed RA, et al. Zingerone Attenuates Carfilzomib-Induced Cardiotoxicity in Rats through Oxidative

Stress and Inflammatory Cytokine Network. *Int J Mol Sci.* 2022;23(24):15617.

19. Yagmurca M, Bas O, Mollaoglu H, Sahin O, Nacar A, Karaman O, et al. Protective effects of erdosteine on doxorubicin-induced hepatotoxicity in rats. *Arch Med Sci.* 2007;38(4):380-5.

20. Mohammad SI, Mustafa IA, Abdulqader S. Ameliorative effect of the aqueous extract of *Zingiber officinale* on the cadmium-induced liver and kidney injury in female rats. *Jordan J Biol Sci.* 2013;6(3):231-234.

21. El-Sharaky AS, Newairy AA, Kamel MA, Eweda SM. Protective effect of ginger extract against bromobenzene-induced hepatotoxicity in male rats. *Food Chem Toxicol.* 2009;47(7):1584-90.

22. Periyasamy L, Jambhulka, Deshiredy S, Jestadi DB. Quercetin Attenuating Doxorubicin Induced Hepatic, Cardiac and Renal Toxicity in Male Albino Wistar Rats. *Am J Phytomed Clin Ther;* 2014;2:985-1004.

23. Sréter I, Kiss A, Cornides A, Vereckei A, Toncsev H, Fehér J. Inhibition of doxorubicin-induced liver toxicity by a new dihydroquinoline type antioxidant. *Acta Physiol Hung.* 1984;64(3-4):431-5.

24. Rashid S, Ali N, Nafees S, Ahmad ST, Arjumand W, Hasan SK, Sultana S. Alleviation of doxorubicin-induced nephrotoxicity and hepatotoxicity by chrysin in Wistar rats. *Toxicol Mech Methods.* 2013;23(5):337-45.

25. Nagai K, Oda A, Konishi H. Theanine prevents doxorubicin-induced acute hepatotoxicity by reducing intrinsic apoptotic response. *Food Chem Toxicol.* 2015;78:147-52.

26. Doroshow JH, Locker GY, Baldinger J, Myers CE. The effect of doxorubicin on hepatic and cardiac glutathione. *Res Commun Chem Pathol Pharmacol.* 1979;26(2):285-95.

27. Revis NW, Marusic N. Glutathione peroxidase activity and selenium concentration

Zingerone Protective Effect Against Hepatotoxicity

in the hearts of doxorubicin-treated rabbits. *J Mol Cell Cardiol.* 1978;10(10):945-51.

28. Sarvazyan NA, Askari A, Huang WH. Effects of doxorubicin on cardiomyocytes with reduced level of superoxide dismutase. *Life Sci.* 1995;57(10):1003-10.

29. Alibakhshi T, Khodayar MJ, Khorsandi L, Rashno M, Zeidooni L. Protective effects of zingerone on oxidative stress and inflammation in cisplatin-induced rat nephrotoxicity. *Biomed Pharmacother.* 2018;105:225-232.