

# Whole-Exome Sequencing Identified a Novel Variant (C.405\_422+39del) in *DSP* Gene in an Iranian Pedigree with Familial Dilated Cardiomyopathy

Yeganeh Eshaghkhani<sup>1</sup>, Arezoo Mohamadifar<sup>2</sup>, Mostafa Asadollahi<sup>1</sup>,  
Mahdieh Taghizadeh<sup>3</sup>, Arezou Karamzade<sup>1</sup>, Mohammad Saberi<sup>1</sup>,  
Parisa Nourmohammadi<sup>3</sup>, Zahra Golchehre<sup>1</sup>, Ahmad Amin<sup>2</sup>,  
Mohammad Keramatipour\*<sup>1,3</sup>

## Abstract

**Background:** Dilated cardiomyopathy (DCM) is a progressive heart condition characterized by left ventricular chamber enlargement associated with systolic heart failure and prolonged action potential duration. Genetic variations in genes that encode cytoskeleton, sarcomere, and nuclear envelope proteins are responsible for 45% of cases. In our study, we focused on a pedigree with familial DCM to decipher the potential genetic cause(s) in affected members developing arrhythmia, end-stage heart failure, and sudden death.

**Methods:** Whole-exome sequencing (WES) was exploited for a 27-year-old heart-transplanted female as the proband, and the derived data were filtered using the standard pipelines.

**Results:** A 57-nucleotide deletion (c.405\_422+39del) in the desmoplakin gene (*DSP*) (NM\_004415.4) was identified as a novel pathogenic variant. Familial segregation analysis indicated that this variant is present in clinically affected members and absent in unaffected members.

**Conclusions:** It seems that the detected variant induces intron retention, resulting in a premature stop codon in intron 3 of *DSP* leading to production of a truncated, nonfunctional protein. Additionally, it can trigger a nonsense-mediated mRNA decay pathway associated with inhibition of protein production. The present study results illustrated that a novel deletion in *DSP* can cause DCM in an Iranian family.

**Keywords:** Desmoplakin, Dilated cardiomyopathy, Pathogenic variant, Whole-exome sequencing.

## Introduction

Dilated cardiomyopathy (DCM) is a serious myocardial disorder in which myocardium becomes weak and stretched, so that systolic function becomes impaired because of the enlargement and insufficient contraction of ventricles, a condition that leads to heart failure, arrhythmia, and sudden

death (1-3). The prevalence of DCM was reported as 1 out of 2500 in 1989, but was estimated at 1 out of 250 based on later findings (4). The disease is more common in men than in women. It is one of the most common causes of heart failure and heart transplantation worldwide (5). Approximately 45% of DCM cases have a genetic

1: Department of Medical Genetics, Faculty of Medicine, Tehran University of Medical Sciences, Tehran, Iran.

2: Rajaie Cardiovascular, Medical and Research Center, Iran University of Medical Science, Tehran, Iran.

3: Watson Genetic Laboratory, North Kargar Street, Tehran, Iran.

\*Corresponding author: Mohammad Keramatipour; Tel: +98 21 8895 3005; E-mail: keramatipour@sina.tums.ac.ir.

Received: 30 Jan, 2021; Accepted: 13 Feb, 2020

etiology; however, pathogenic variations have been found in only 30–40% of patients (6–8). It is shown that genetic variations in more than 50 genes encoding constituents of the cytoskeleton, sarcomere, nuclear membrane, and mitochondrial proteins can cause DCM, indicating considerable genetic heterogeneity in genetic cases of DCM (9–11). Up to 90% of familial DCM cases follow an autosomal dominant inheritance mode, and about 10% of cases may be inherited in an autosomal recessive, X-linked recessive, or mitochondrial pattern (12). *DSP* (MIM 125647) encodes a desmosomal plaque component, desmoplakin, and its variations have been attributed to a variety of disorders related to heart muscle, hair, skin, and tooth tissues (13). Taking advantage of whole-exon sequencing (WES) technology and gene annotation, a novel small deletion variant (c.405\_422+39del) was detected in *DSP* that may underlie the pathogenesis of DCM, and the results were validated by Sanger sequencing.

## Materials and Methods

### Case report

An Iranian family with autosomal dominant familial DCM has been referred (Fig. 1). The diagnosis of DCM was made for the proband and the other affected members of the family by investigating their detailed clinical histories, physical examinations, and transthoracic echocardiography. The proband (IV: 9), a 29-year-old female diagnosed with DCM at age 20, had received a heart transplant at age 27. She had manifested the typical clinical features of hereditary DCM, including left ventricular enlargement, severely reduced systolic function, and ejection fraction equal to 10–15%. In addition, biochemical tests showed a significant increase in pro-b-type natriuretic peptide (NT-proBNP) concentration (equal to 16222 pg/ml). The exercise test had showed low load,  $V_{CO_2}$ ,  $V_{O_2}$ ,  $V_E$ ,  $V_t$ , HR, O<sub>2</sub>Pulse, P<sub>ET</sub>O<sub>2</sub>, P<sub>ET</sub>CO<sub>2</sub>,  $V_{O_2}/I_s$  kg, normal RER,  $B_f$ ,  $V_{O_2}/WR$ , and high HRR, BR,  $VE/V_{CO_2}$ ,  $V_d/V_t$  and  $VO_{2AT}/VO_2$  parameters. She also had experienced a spontaneous abortion.

Proband's eldest sister (IV: 7) is a 31-year-old female with DCM. Her NT-proBNP concentration was 1742 pg/ml at its highest. On

echocardiography her left ventricular ejection fraction (LVEF) was 45%. Proband's other sister (IV: 10) is a 22-year-old female who had apparently normal findings in cardiac evaluations. Proband's mother (III: 3) was a 52-year-old female with DCM. Her NT-proBNP concentration was 3918 pg/ml at its highest. On echocardiography her LVEF was 20% and she died when she was 53 years old. Proband's mother uncle (III: 5) is a 34-year-old female with DCM. Her NT-proBNP concentration was 4672 pg/ml, and on echocardiography her left ventricle was severely enlarged and LVEF was 10–15%. Proband's niece (V: 3) had suffered from a cardiac malformation.

### Ethical statement

This study was approved by the Ethics Committee of Tehran University of Medical Sciences. Written informed consents for genetic investigation and publication of clinical information were obtained from all study participants.

### Subjects

Available members of the pedigree were enrolled in the present study. Two experienced cardiologists comprehensively examined ten family members. Peripheral venous blood from the proband (IV: 9) and five appropriate members with close relationships to the proband (III: 2, III: 5, IV: 5, IV: 7 and IV: 10), including two affected individuals (III: 5 and IV: 7), was collected for the genetic study. All medical records of healthcare, routine physical, and fundus examinations were collected.

### Whole-exome sequencing

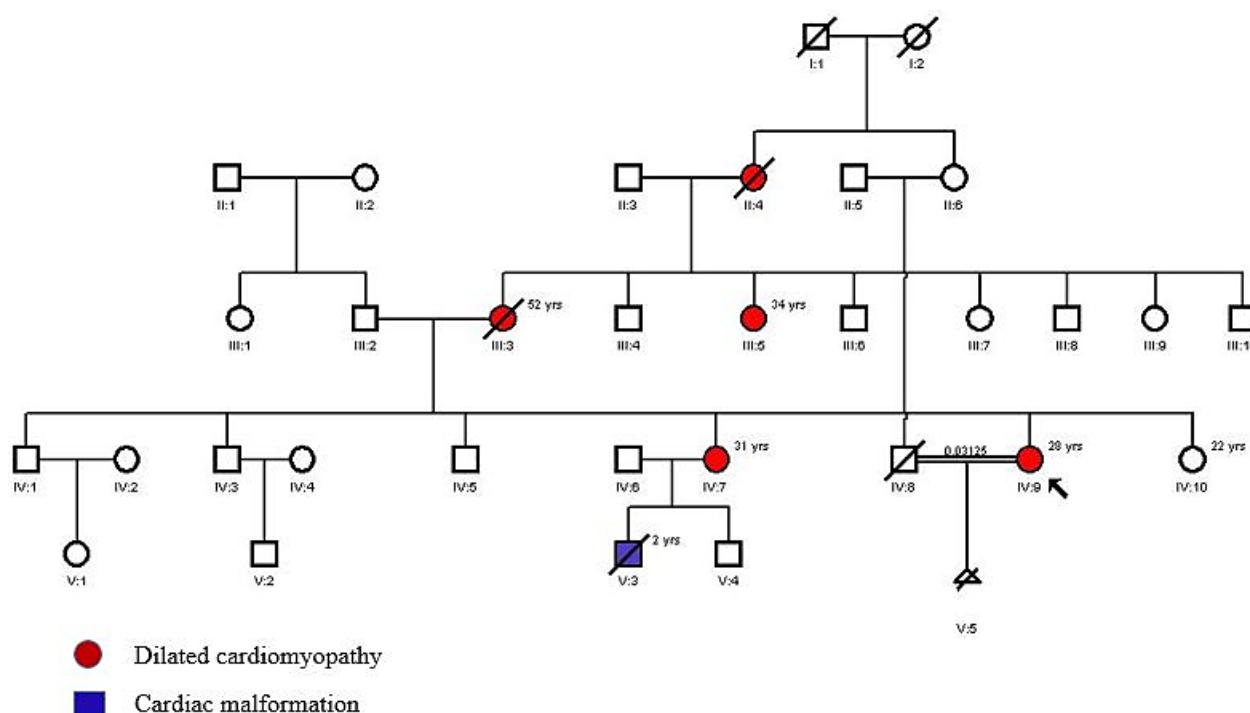
Genomic DNA was isolated from peripheral venous blood cells using the Exgene™ Blood SV DNA purification kit (GeneAll®, Korea). DNA concentrations were determined on a Thermo Scientific™ Nanodrop 2000. Exome sequencing was performed on the proband (IV: 9) by CeGaT GmbH (Tübingen, Germany). A paired-end DNA library was constructed, and the whole-exome capturing was performed using the Twist Human Core

Exome Kit. After quality assessment, the captured DNA library was sequenced on the Illumina NovaSeq platform following the Illumina protocols (Illumina Inc., San Diego, CA, U.S.A.) with an average coverage of nearly 100×. About 97% of the targeted bases were covered more than 10 times.

### Bioinformatics analysis

After the base calling and quality assessment of sequencing data, sequence reads were analyzed and aligned to the human reference genome applying the alignment tools. Burrows-Wheeler Aligner (BWA) and Assembly Based ReAligner (ABRA) tools were applied to sort sequencing alignments and mark duplicate reads, respectively. The single nucleotide polymorphisms (SNPs) and insertion–deletion mutations (indels) were called using the GATK HaplotypeCaller program, and subsequently annotated using the ANNOVAR program. Generally, variants associated with monogenic disorders are rare in public variant databases. With specific

settings, variants were filtered using datasets from the SNP database (dbSNP, build 151), 1000 Genomes Project (2014 September release), Genome Aggregation Database (gnomAD), Haplotype Reference Consortium (HRC), and the Exome Aggregation Consortium (ExAC). Only variants, including SNPs and indels located in exonic regions or canonical splicing sites, were deemed plausible candidates, and prioritized for further analysis. *In silico* analysis applying Sorting Intolerant from Tolerant (SIFT), Polymorphism Phenotyping version 2 (PolyPhen-2), MutationTaster, Protein Variation Effect Analyzer (PROVEAN), Functional Analysis through Hidden Markov Models (FATHMM), and Combined Annotation Dependent Depletion (CADD) were employed to obtain a functional prediction. A left-plausible candidate-gene variant associated with cardiomyopathy disorders was then prioritized for confirmation in the validation stage.



**Fig. 1.** The DCM-affected family pedigree. Members are identified by generations and numbers. The arrow appoints the family proband (IV: 9). In this pedigree, white symbols represent unaffected members; red and blue symbols represent affected; squares represent males, and circles females; parallel lines indicate the consanguineous marriage.

### Co-segregation analysis

Segregation analysis was applied to involved family members using PCR-Sanger sequencing in accordance with the WES results. Primer pairs were designed using Gene Runner 6.0 software, and their sequences are as follows:

forward:

5'-CAAGGGGAAGGTTAGCATTTCAGCA-3'.

reverse:

5'-CTTGGGAACATTTGTGCTGCCTTCA-3'.

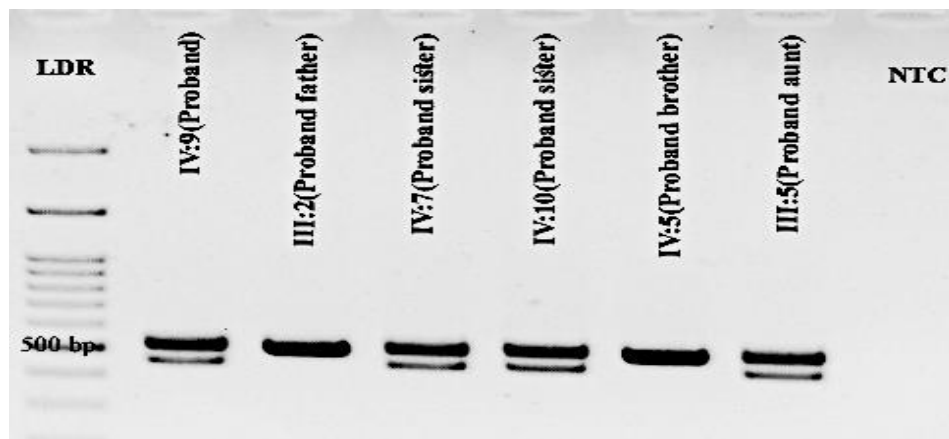
The PCR products then were evaluated by gel electrophoresis using 1.5% (w/v) agarose gel.

### Results

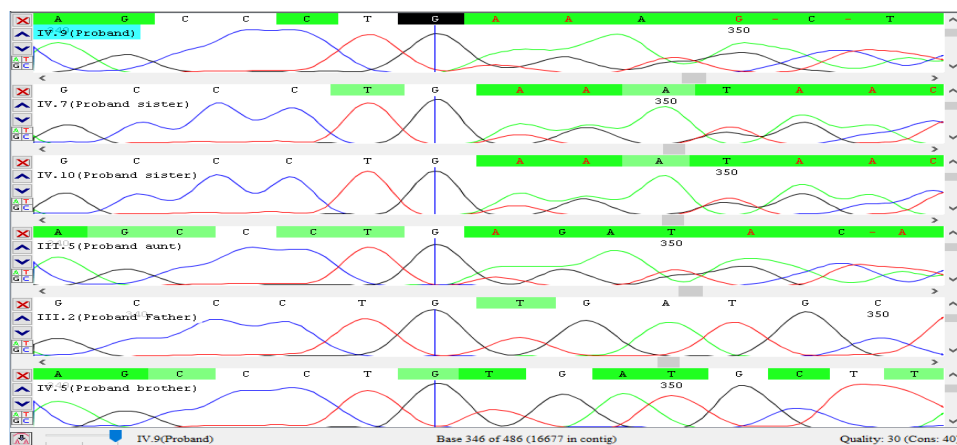
To reveal the disease-causing genetic variant(s), the genomic DNA obtained from

the proband was investigated by WES. Then, the detected variant (Table 1) was validated by PCR-gel electrophoresis and Sanger sequencing. As expected, the DNA bands represented two different fragment sizes in heterozygous status of the deletion in the proband (IV: 9), IV: 7, IV: 10, and III: 5 (Fig. 2A). Moreover, we found the heterozygous deletion disrupting the pattern of base arrangement in the sequencing chromatograms of them (Fig. 2B). The gel electrophoresis findings of III: 2 and IV: 5 individuals displayed a single band in expected size, and their sequencing chromatograms had an intact base arrangement.

A)



B)



**Fig. 2.** Identification and molecular validation of c.405\_422+39del variant in the patient and her family members. A) Result of electrophoresing PCR products of the proband (IV: 9), III: 2, IV: 7, IV: 10, IV: 5, III: 5, and negative control (NTC) on 1.5% gel agarose. The LDR lane contains ladder 100bp+3kb. Columns with two bands represent the heterozygous deletion. (B) The sequencing chromatograms indicate a disrupted base reading pattern after position G nucleotide (the blue vertical line) in the proband (IV: 9) and IV: 7, IV: 10, III: 5.

**Table 1.** Details of the Variant Identified. Variant annotation, according to the ANNOVAR program is based on RefSeq gene annotation.

<b>Chr</b>	chr6
<b>Start</b>	7558480
<b>End</b>	7558536
<b>Ref</b>	TGATGCTTACCAGAAAAGGTATTGTCCACAGAGCATGGATCGGGCAGTCCCCATGAA
<b>Alt</b>	-
<b>zygosity</b>	HET
<b>Gene.refGene</b>	exonic
<b>ExonicFunc.refGene</b>	DSP
<b>AAChange.refGene</b>	DSP:NM_001008844:exon3:c.405_422del:p.C135_R141delinsW, DSP:NM_001319034:exon3:c.405_422del:p.C135_R141delinsW, DSP:NM_004415:exon3:c.405_422del:p.C135_R141delinsW
<b>Xref.refGene</b>	Arrhythmogenic right ventricular dysplasia 8, Autosomal dominant. Cardiomyopathy, dilated, with woolly hair and keratoderma, Autosomal recessive. Dilated cardiomyopathy with woolly hair, keratoderma, and tooth agenesis, Autosomal dominant. Epidermolysis bullosa, lethal acantholytic, Autosomal recessive. Keratosi palmoplantaris striata II; Skin fragility-woolly hair syndrome, Autosomal recessive

Considering appearance of the pedigree and inheritance pattern, we assumed that the causative variant(s) might be inherited in heterozygous status; subsequently, several filtering steps were applied to prioritize the variants in terms of: (1) having minor allele frequency less than 0.01 in the 1000 Genomes Project (<http://www.internationalgenome.org/>), ExAC (<http://exac.broadinstitute.org/>) and gnomAD (<http://gnomad.broadinstitute.org/>) databases; (2) occurrence in the coding regions or essential/canonical splicing sites; (3) having potential damaging or deleterious functional effects that were predicted by multiple lines of *in silico* computational analysis; (4) occurrence in a candidate gene related to inherited DCM. The filtering procedure was carried out with assuming the homozygous status of inheritance to be on the safe side, but this did not lead to any candidate variant in the family.

The list of candidate variants was reduced using Phenolyzer (<http://phenolyzer.wglab.org/>), Face2Gene (<https://www.face2gene.com/>), and Varcards (<http://159.226.67.237/sun/varcards/>). The suspected pathogenic variants were checked in the HGMD® (The Human Gene Mutation Database) and ClinVar databases. Further investigation analyzed the variant frequency on Iranome (a catalog of genomic variations in the Iranian population) as the in-house database.

Finally, we identified a novel heterozygous small deletion in the family and classified it as a pathogenic variant based on the American College of Medical Genetics and Genomics (ACMG) guidelines.

## Discussion

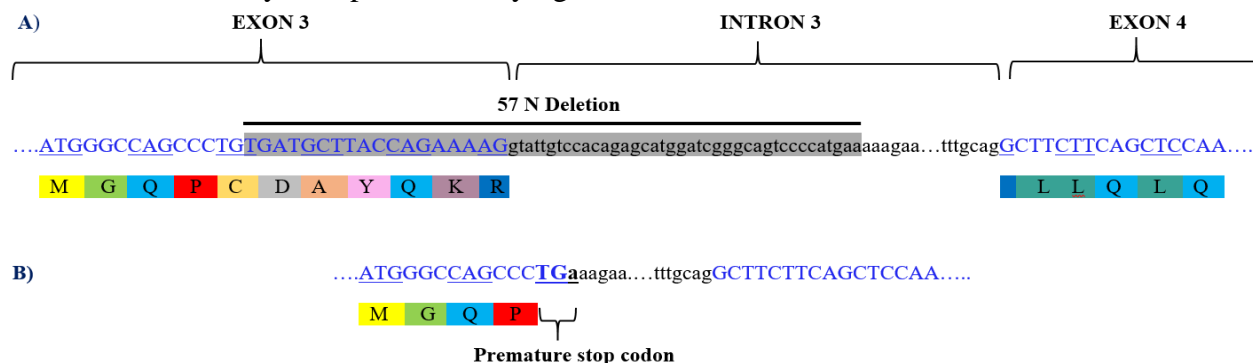
Dilated cardiomyopathy is the most common non-ischemic heart condition described by the remodeling and contractile impairment of the left ventricle in absence of other disorders affecting its performance (14). Dilated cardiomyopathy onset typically occurs during adulthood but can occur any time from infancy to adolescence. Dilated cardiomyopathy has a variable phenotypic expressivity among affected patients. Clinical severity may also range from asymptomatic to mild to acute heart failure and sudden cardiac death (15). To date, more than 50 genes related to DCM have been reported (16). However, the molecular basis of a significant number of cardiomyopathies is still uncertain. The next-generation sequencing (NGS) technologies are powerful procedures that can fulfill this gap, so they have significantly accelerated the detection of disease-causing genetic changes. Among NGS techniques, WES has emerged as a strong and cost-effective method to detect the causative variant(s) in diseases with locus heterogeneity (17, 18). *DSP* comprises 24 exons and encodes desmoplakin,

an essential protein with a key role in desmosomal adhesions (19, 20). Pathogenic variants in *DSP* have been associated with skin, hair, tooth, and heart disorders in humans. The affected members of this study had wooly hairs, but they were not investigated for possible skin and tooth anomalies. However, no defects of these types were found in the patients' records. Until March 2020, the ClinVar database lists 256 truncating *DSP* variants, of which 232 (90.6%) are classified as pathogenic or likely pathogenic. The variants with non-pathogenic classification have been localized in the region encoding the protein's C terminus. Since this gene is dosage sensitive, truncating variants (especially N terminus variants) can lead to cardiac disease by a haploinsufficiency mechanism (ClinGen haploinsufficiency Score: 1) (21, 22). The identified variant (c.405\_422+39del) deletes 57 nucleotides from the genomic DNA, of which 18 nucleotides are located in exon 3, and 39 nucleotides remain in intron 3 (Fig. 3A). This variation can cause disease with several scenarios such as p.C135\_R141delinsW, exon skipping, using an exonic cryptic splicing donor site, and using an intronic cryptic splicing donor site. However, it seems that the most probable scenario is intron retention. Thus, the identified variant leads to intron 3 retention by deleting a normal splicing donor site (Fig. 3B). Subsequently, this variant leads to a premature stop codon, and is assumed to induce nonsense-mediated mRNA decay. It was shown in a recent study that the truncating *DSP* variant demonstrates relatively low penetrance by age

40 (23). In the present study, all family members carrying the variant expressed cardiac involvement, except for proband's younger sister (IV: 10) who is apparently healthy due to her young age, although she is expected to express DCM in the future.

Multiple lines of evidence support the pathogenicity of the variant detected in the present study: a) it is a null variant; a deletion encompassing a canonical splice site (donor GT in 5' end of intron 3) affecting *DSP* mRNA splicing, which is a reported mechanism of disease associated with DCM and several other phenotypes related to incomplete integrity of heart muscle, hair, skin, and tooth tissues; b) this variant is absent in public and local allele frequency databases such as 1000 Genomes Project, gnomAD database, and Iranome. Additionally, no publication has introduced this deletion as a causative variant, suggesting it is a novel variation; c) this small deletion was not detected in other family members who were not diagnosed with DCM; and d) it is predicted as a pathogenic variant (vs. benign predictions) by *in silico* computational prediction tools.

In conclusion, combining WES with filtering tools, we introduce a novel *DSP* deletion variant (c.405\_422+39del) that may be a causative variant in a heart-transplanted case of DCM and other affected family members. The present study may help to further understand the relationship between *DSP* and DCM and introduce a novel marker for future genetic diagnosis and counseling of families with DCM.



**Fig. 3.** The consequence of identified deletion. (A) Normal splicing. During normal splicing, Intron 3 is removed, and exon sequences are translated into the corresponding amino acids in a correct reading frame. (B) Intron retention scenario. The identified variant (c.405\_422+39del) deletes 57 nucleotides from the genomic DNA, of which 18 nucleotides are located in exon 3, and 39 nucleotides remain in intron 3. Deletion of the normal splicing donor site led to intron 3 retention and subsequently this variant, resulting in a premature stop codon.

## Acknowledgements

Our team thanks the family members who participated in this study. There are no conflicts of interest.

## References

- Pinto YM, Elliott PM, Arbustini E, Adler Y, Anastasakis A, Böhm M, et al. Proposal for a revised definition of dilated cardiomyopathy, hypokinetic non-dilated cardiomyopathy, and its implications for clinical practice: a position statement of the ESC working group on myocardial and pericardial diseases. *Eur Heart J*. 2016;37(23), 1850-8.
- Yancy CW, Jessup M, Bozkurt B, Butler J, Casey DE, Drazner MH, et al. (2013). 2013 ACCF/AHA guideline for the management of heart failure: a report of the American College of Cardiology Foundation/American Heart Association Task Force on Practice Guidelines. *J Am Coll Cardiol*. 2013;62(16):e147-239.
- Elliott P, Andersson B, Arbustini E, Bilinska Z, Cecchi F, Charron P, et al. Classification of the cardiomyopathies: a position statement from the European Society Of Cardiology Working Group on Myocardial and Pericardial Diseases. *Eur Heart J*. 2008;29(2),270-6.
- Hershberger RE, Hedges DJ, Morales A. Dilated cardiomyopathy: the complexity of a diverse genetic architecture. *Nature Reviews Cardiology*. 2013;10(9):531-547.
- Maron BJ, Towbin JA, Thiene G, Antzelevitch C, Corrado D, D Arnett, et al. Contemporary definitions and classification of the cardiomyopathies: an American Heart Association scientific statement from the council on clinical cardiology, heart failure and transplantation committee; quality of care and outcomes research and functional genomics and translational biology interdisciplinary working groups; and council on epidemiology and prevention. *Circulation*. 2006;113(14):1807-16.
- Long PA, Larsen BT, Evans JM, et al. Exome sequencing identifies pathogenic and modifier mutations in a child with sporadic dilated cardiomyopathy. *J Am Heart Assoc*. 2015;4(12):e002443.
- Piran S, Liu P, Morales A, Hershberger RE. (2012). Where genome meets phenome: rationale for integrating genetic and protein biomarkers in the diagnosis and management of dilated cardiomyopathy and heart failure. *J Am Coll Cardiol*. 2012;60(4):283-9.
- Semsarian C, MacDonald P, Weintraub RG. Dilated cardiomyopathy. *Lancet*. 2017;390(10092):400-414.
- Japp AG, Gulati A, Cook SA, Martin R, Cowie, Sanjay KP. The diagnosis and evaluation of dilated cardiomyopathy. *J Am Coll Cardiol*. 2016;67(25):2996-3010.
- Haas, J., Frese, K. S., Peil, B., et al. (2015). Atlas of the clinical genetics of human dilated cardiomyopathy. *Eur Heart J*. 2015;36(18):1123-35a.
- McNally EM, Mestroni L. Dilated cardiomyopathy: genetic determinants and mechanisms. *Circ Res*. 2017;121(7):731-748.
- Charron P, Arad M, Arbustini E, Basso C, Bilinska Z, Elliott P, et al. Genetic counselling and testing in cardiomyopathies: a position statement of the European Society of Cardiology Working Group on Myocardial and Pericardial Diseases. *Eur Heart J*. 2010;31(22):2715-26.
- Rampazzo A, Nava A, Malacrida S, Beggagna G, Bauce B, Rossi V, et al. Mutation in human desmoplakin domain binding to plakoglobin causes a dominant form of arrhythmogenic right ventricular cardiomyopathy. *Am J Hum Genet*. 2002; 71(5):1200-6.
- Elliott P. Diagnosis and management of dilated cardiomyopathy. *Heart*. 2000;84(1):106.
- Hershberger R E, Morales A, Siegfried JD. (2010). Clinical and genetic issues in dilated cardiomyopathy: a review for genetics professionals. *Genet Med*. 2010;12(11):655-67.

16. Mestroni L, Taylor MR. Genetics and genetic testing of dilated cardiomyopathy: a new perspective. *Discov Med*. 2013;15(80):43-9.
17. Majewski J, Schwartzenuber J, Lalonde E, Montpetit A, Jabado N, et al. What can exome sequencing do for you?. *J Med Genet*. 2011;48(9):580-9.
18. Norton N, Li D, Hershberger R E. (2012). Next-generation sequencing to identify genetic causes of cardiomyopathies. *Curr Opin Cardiol*. 27(3):214-20.
19. Smith E A, Fuchs E. Defining the interactions between intermediate filaments and desmosomes. *J Cell Biol*. 1998;141(5):1229-1241.
20. Garrod D, Chidgey M. Desmosome structure, composition and function. *Biochim Biophys Acta*. 2008;1778(3):572-87.
21. Bauce B, Basso C, Rampazzo A, Beffagna G, Daliento L, Frigoet G, et al. Clinical profile of four families with arrhythmogenic right ventricular cardiomyopathy caused by dominant desmoplakin mutations. *Eur Heart J*. 2005;26(16):1666-75.
22. Rasmussen TB, Hansen J, Nissen PH, Dalager S, Jensen UB, Kim WY, et al. Protein expression studies of desmoplakin mutations in cardiomyopathy patients reveal different molecular disease mechanisms. *Clin Genet*. 2013;84(1):20-30.
23. Heliö K, Kangas-Kontio T, Weckström S, Vanninen SUM, Aalto-Setälä K, Alastalo T, et al. *DSP* p.(Thr2104Glnfs\*12) variant presents variably with early onset severe arrhythmias and left ventricular cardiomyopathy. *BMC Med Genet*. 2020;21(1):19.