

# Zinc Oxide Nanoparticles Ameliorate Histological Alterations Through Apoptotic Gene Regulation in Rat Model of Liver Ischemia-Reperfusion Injury

Maryam Jafar Sameri<sup>1</sup>, Feryal Savari\*<sup>2</sup>, Seyyed Ali Mard<sup>3</sup>,  
Anahita Rezaie<sup>4</sup>, Mojtaba Kalantar<sup>5</sup>

## Abstract

**Background:** Organ ischemia-reperfusion (IR) is a common clinical condition associated with various situations such as trauma surgery, organ transplantation, and myocardial ischemia. Current therapeutic methods for IR injury have limitations, and nanotechnology, particularly zinc oxide nanoparticles (ZnO NPs), offers new approaches for disease diagnosis and treatment. In this study, we investigated the protective and anti-apoptotic effects of ZnO NPs in liver ischemia-reperfusion (IR) injury in rats.

**Methods:** Forty-eight male rats were divided into six groups: sham, ZnO5, ZnO10, ischemia-reperfusion (IR), IR+ZnO5, and IR+ZnO10. The protective effect of ZnO NPs was evaluated by liver enzymes (AST, ALT, Bilirubin, ALP), biochemical (TAC, TNF- $\alpha$ , and MDA), molecular examinations (Bcl2, BAX), and histopathological evaluations (H&E, TUNEL).

**Results:** Pre-treatment with ZnO5 and ZnO10 improved hepatic function in IR liver injury, attenuated the levels of oxidants ( $P = 0.03$ ) and inflammatory mediators, and reduced apoptosis ( $P = 0$ ). ZnO10 was found to have a greater effect on ischemic reperfusion injury than ZnO5 did. Histopathological examination also showed a dose-dependent decrease in alterations in the IR+ZnO5 and IR+ZnO10 groups.

**Conclusion:** Administration of ZnO5 and ZnO10 improved liver function after IR. The findings of this study suggest that ZnO NPs have a protective effect against oxidative stress and apoptosis in liver ischemia-reperfusion injury in rats. These results may have important implications for developing advanced methods in ischemia-reperfusion treatment.

**Keywords:** Anti Apoptotic Protein, Caspase 3, Metal Nanoparticle, Zinc Compounds.

## Introduction

Organ ischemia-reperfusion (IR) is a pathological condition characterized by a lack of nutrient and oxygen supply, followed by a reperfusion phase (1, 2). IR injury is a common clinical case, accounting for approximately 30-

40% of deaths in intensive care units, and is associated with various conditions, such as myocardial ischemia, trauma surgery, hemorrhagic shock, thrombolytic therapy, coronary angioplasty, and organ

1: Department of physiology, medicine faculty, Abadan University of Medical Sciences, Abadan, Iran.

2: Department of Medical Basic Sciences, Shoushtar Faculty of Medical Sciences, Shoushtar, Iran.

3: Clinical Sciences Research Institute, Alimentary Tract Research Center, Department of Physiology, The School of Medicine, Ahvaz Jundishapur University of Medical Sciences, Ahvaz, Iran.

4: Department of Pathobiology, School of Veterinary Medicine, Shahid Chamran University of Ahvaz, Ahvaz, Iran.

5: Department of Occupational Health, Shoushtar Faculty of Medical Sciences, Shoushtar, Iran.

\*Corresponding author: Feryal Savari; Tel: +98 9166101504; E-mail: savari.f@ajums.ac.ir.

Received: 16 Feb, 2024; Accepted: 19 May, 2024

transplantation (3).

During hepatocyte ischemia, alterations in H<sup>+</sup>, Na<sup>+</sup>, and Ca<sup>+</sup> homeostasis are accompanied by reduced ATP levels (4, 5). The reperfusion phase leads to the production of reactive oxygen species (ROS), resulting in biomolecular oxidation and cell dysfunction (6). Current research in the field of liver IR injury are mainly focused on administering antioxidants to inhibit excessive ROS production (7-9).

Nano zinc oxide is a new type of zinc with unique biological properties and low toxicity (10). It strengthens the antioxidant capacity and has a greater absorption power than other zinc-containing compounds (11). Recent research has demonstrated that zinc oxide nanoparticles (ZnO NPs) possess anti-cancer, antimicrobial, and antioxidant properties. Nano-ZnO ameliorates the formation of fibrotic foci and proliferation of fibrotic tissue, aspartate aminotransferase (AST), alanine aminotransferase (ALT), and lactate dehydrogenase (LDH) in experimental models of liver injury (12).

Zinc oxide nanoparticles (ZnO NPs) have emerged as promising candidates for the treatment of liver ischemia-reperfusion injury given their safety profile and potent antioxidant and anti-inflammatory properties. In addition, while the therapeutic potential of ZnO NPs has been recognized, it is essential to consider the potential toxic effects of nanoparticles, particularly in the context of liver injury (13, 14). Previous studies have highlighted the importance of understanding the dosage and probability of the protective effects of ZnO NPs, especially in the context of liver ischemia-reperfusion injury. By elucidating the balance between the therapeutic benefits and potential toxic effects of ZnO NPs in the context of liver IR injury, this research provides valuable insights into the development of effective and safe nanoparticle-based therapies for ischemia-reperfusion injury.

## Materials and Methods

### *Animal grouping and surgical procedures*

Male Wistar rats, 8-12 weeks old (200-250 g weight), were purchased from the animal center of Ahvaz Jundishapur University of Medical Sciences (AJUMS), Iran. The animals with free access to laboratory chow and water are housed at 22±2 °C under a 12-h light/dark cycle at the animal laboratory center of AJUMS. All protocols were performed under the ethics committee of the Shoushtar Faculty of Medical Sciences (IR.SHOUSHTAR.REC.1400.009). The animals were divided into six groups randomly (n=8) including; 1: Sham, 2: ZnO5, 3: ZnO10, 4: Ischemia-Reperfusion (IR), 5: IR+ ZnO5, and 6: IR+ ZnO10 (15).

The animals in the pre-treatment groups, including ZnO5, ZnO10, IR+ZnO5, and IR+ZnO10, received zinc oxide nanoparticles (doses of 5 and 10 mg/kg) as intraperitoneal (i.p.) injections (16, 17) for three consecutive days. Rats were starved for 16-18 hours before the experiments, with free access to water.

IR surgery was performed in the IR, IR+ZnO5, and IR+ZnO10 groups. Animals were anesthetized by administering a combination of (ketamine 60 mg/kg and xylazine 15 mg/kg) (Alfasan Company, Netherlands), and a 3-4 cm abdominal incision was made. The hepatic artery and portal vein were clamped using an atraumatic clip for 45 minutes to induce partial hepatic ischemia (70%). Animals were rendered ischemic by administering a combination of ketamine (60 mg/kg) and xylazine (15 mg/kg) anesthesia (Alfasan Company, Netherlands). A 3-4 cm abdominal incision was made, and the hepatic artery and portal vein were clamped using a gentle clip to induce partial hepatic ischemia (70%) for a duration of 45 minutes. Throughout the procedure, the liver was kept moist using sterile saline-soaked gauze, and the body temperature was maintained at 37 °C by a homoeothermic blanket system (Harvard,

UK). Following a reperfusion period of 1 hour, blood samples were obtained through a cardiac puncture for serological analysis. Additionally, liver samples were frozen in liquid nitrogen for subsequent evaluation of molecular and oxidant status. One liver sample was preserved in formalin for H&E and TUNEL staining.

### ***Preparation of nanoparticles suspension***

ZnO NPs were prepared as follows: the suspension of ZnO NPs with the sizes of 10-30 nm (USnano, Co, USA) was prepared by sonication in 0.9% saline for 16 minutes to completely disperse the particles. The suspension was then injected immediately. To ensure non-aggregation, the NPs were shaken before every I.P. injection.

### ***Transmission Electron Microscopy (TEM)***

For TEM imaging of zinc oxide nanoparticles, a drop of the nanoparticle suspension was deposited onto a carbon-coated copper grid. After air drying, the grid was loaded into a high-resolution TEM equipped with a digital camera (H9500-Hitachi, Japan). By optimizing imaging conditions, including focus, magnification, and exposure, high-resolution images of the nanoparticles were obtained (18).

### ***Serum Biochemical Examination***

Serum from the blood samples was transferred to a microtube and maintained at 20 °C after centrifugation for 5 minutes at 12,000 g. The following enzymes were measured on an Auto Chemistry Analyzer (BT-1500, Italy), according to the kit's instructions: AST, ALT, total bilirubin (T.Bili), and alkaline phosphatase (ALP).

### ***Histological Examination***

To evaluate liver histology, formalin-fixed liver tissues were sectioned at a thickness of 5 µm and placed in a small mold filled with melted paraffin. After graded alcohol dehydration, H&E staining performed. For histological evaluation, the tissue sections were carefully examined by a skilled

pathologist to assess the presence of necrosis and hemorrhage and were imaged using a light microscope (Zeiss, Swiss).

### ***Terminal dUTP nick-end labeling (TUNEL) assay***

TUNEL staining assay performed according to Elabscience TUNEL apoptosis assay kit (Elabscience, U.S.A) instructions based on our previous method. Briefly, the 5 µm sections were deparaffinized and treated with methanol and H<sub>2</sub>O<sub>2</sub> for 10 minutes. Proteinase was added for 30 minutes at 37 °C after three PBS washes. The sections were then incubated in triton (0.3%) for 10 minutes, washed three times, and incubated for 2 hours with TdT, and liquid around the tissues was dried using an absorbent paper. The DAPI stain was added for 5 minutes, and after washing 4 times with PBS, a mounting medium (containing fluorescent mounting media) was added to seal the slides. Finally, the sections were imaged using a fluorescent microscope (LABOMED, USA). The number of TUNEL-positive cells was counted, and the data were analyzed using the following formula: number of apoptotic cells/total number of nucleated cells × 100% to assess the results in each slide.

### ***ELISA Analysis***

Hepatic tissues were assayed for TNF-α levels using an enzyme-linked immunosorbent assay (ELISA) according to the manufacturer's protocol (Karmania Pars Gene, Iran). Frozen tissue was lysed using RIPA lysis buffer, and samples or different concentrations of standards were added to a microplate pre-coated with a monoclonal antibody specific for mouse TNF-α. After 3 times washing any unbound substances, a specific polyclonal antibody for mouse TNF-α was added to each well. After 3 times of washing, a substrate solution was added to each well. After the enzymatic reaction, the absorbance was measured at 450 nm using an ELISA reader (BioTek, USA). Cytokine concentrations were obtained using a standard curve. The results were expressed as pg/mg protein.

### Real-time quantitative Polymerase Chain Reaction (RT-qPCR)

Hepatic tissue was subjected to total RNA extraction using an RNA extraction kit (RNeasy Mini Kit, Qiagen, Germany) following the provided instructions. Initially, 30 mg of liver tissue was weighed and homogenized by adding 600  $\mu$ l of RLT buffer (WiseTis homogenizer, HG-15D, Witeg, Germany). The lysate was centrifuged, and the clarified homogenate was transferred to a new microtube. Subsequently, ethanol (70%) was added, and the mixture was subjected to three washes. The purity and concentration of the obtained RNA were determined using

spectrophotometry at wavelengths of 260 and 280 nm (NanoDrop 2000; Thermo Fisher Scientific, USA).

The extracted total RNA was utilized for the synthesis of first-strand complementary DNA (cDNA) using a cDNA Synthesis kit (ANACELL, Iran). The cDNA samples were incubated at 70 °C for 5 minutes to halt the reaction. For quantitative PCR, the SYBR Green PCR Master Mix (High ROX; Amplicon, UK) was applied according to the manufacturer's protocol. The data obtained were expressed as fold-increase relative to the control. The primers based on our previous study utilized in the process are listed in Table 1 (19).

**Table 1.** Real-Time PCR Specific Primers (20).

Gene	Forward (5-3)	Reverse (5-3)
BAX	TGAGGTTTATTGGCACCTCC	TTTTCTGGATGAATGGGG
Bcl2	TGAGTACCTGAACCGGCATC	TAGTCCACAAAGGCATCCCA
Caspase3	CCGACTTCCTCTATGCTTACTC	CGTACAGTTTCAGCATGGC
GAPDH	TGCTGGTGCTGAGTATGTCG	CGGAGATGATGACCCTTTG

### Total Antioxidant Capacity and MDA

Tissue Total Antioxidant Capacity (TAC) and Malondialdehyde (MDA) levels were estimated using commercial kits (Kiazist, Iran) according to the manufacturer's protocol. Briefly, 300  $\mu$ l PBS buffer was added to liver tissues and homogenized at 20000  $\times$  g for 5 minutes. The clear supernatant was collected after 15 minutes of centrifugation at 12000  $\times$  g at 4 °C. A 50  $\mu$ l of the sample or different concentrations of the standards were added to a 96-well plate. Then, the cells were incubated with 200  $\mu$ l substrate for 15 minutes and OD red at 560 nm. Concentrations were calculated by a standard curve. For data to be normalized, every sample protein concentration was measured by Bradford assay and expressed as nmol/mg protein.

### Statistical analysis

Results are presented as means  $\pm$  SD. The results were analyzed using one-way ANOVA and Tukey post hoc statistical testing (IBM SPSS statistics 26 and GraphPad Prism 9 for figures illustrating). Significant level assigned on differences less than 0.05.

## Results


### ZnO5 and ZnO10 improve hepatic function in IR liver injury

The nanocrystallization of the ZnO NP was analyzed using transmission electron microscope (TEM) (Fig. 1B).

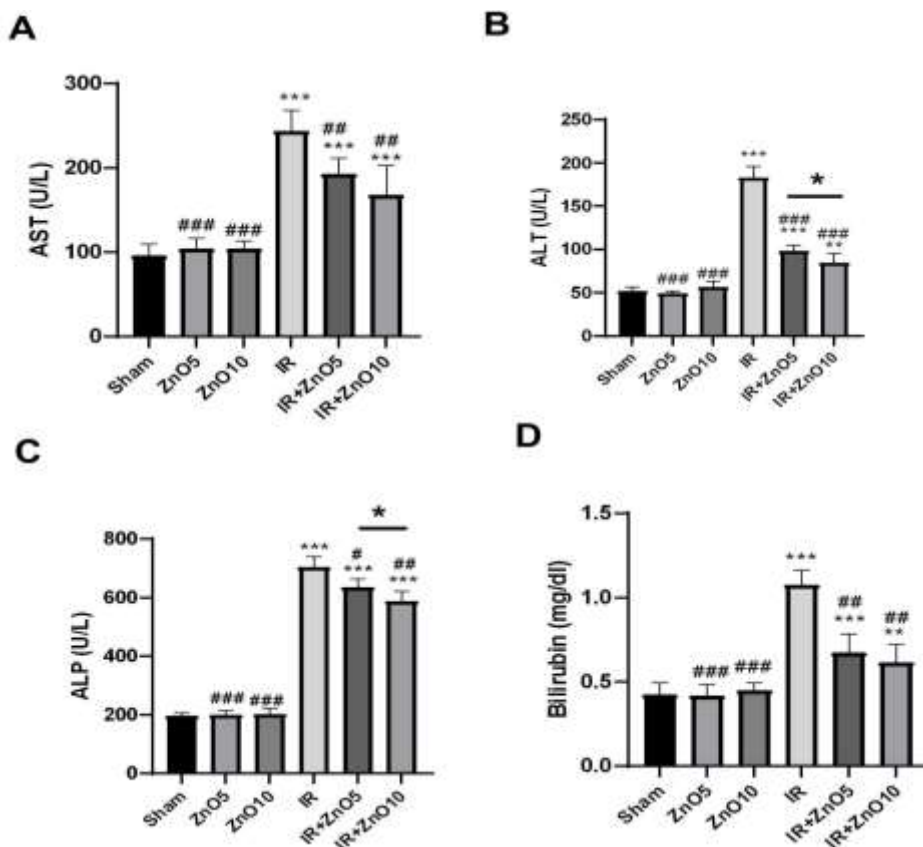
To determine the pre-treatment effects of IR+ZnO5 and IR+ZnO10 on liver injury, serum levels of ALT, AST, T.Bili, and ALP were measured using an autoanalyzer device. Results of liver function analysis showed that the serum levels of ALT ( $P = 0$ ), AST ( $P = 0$ ), T.Bili ( $P = 0$ ), and ALP ( $P = 0$ ) increased significantly after IR injury as compared to the sham group (Fig. 2A). Also, in ZnO NPs pretreatment, in the 5 and 10 mg/kg dose groups (IR+ZnO5 and IR+ZnO10) AST was decreased to, 192.98 ( $P < 0.01$ ) and 167.75 (U/L) ( $P < 0.01$ ), respectively, which were significant in comparison to the IR group. In ZnO5 and ZnO10 treated rats (IR+ZnO5 and IR+ZnO10) ALT levels significantly decreased ( $P = 0$  for both) (Fig. 2). Importantly, ALT levels were significantly higher in the IR+ZnO5 group than the

IR+ZnO10 group ( $P = 0.03$ ), suggesting that ZnO10 might have a greater effect on

improving ischemic-reperfusion injury (Fig. 2B).



**Fig. 1.** Nano-ZnO images provided by TEM. microscope. The transmission electron microscope validated the nanocrystallization of the ZnO NPs. ZnO: zinc oxide; TEM: transmission electron microscope.



**Fig. 2.** Administration of ZnO5 and ZnO10 improved the liver function in Rats following ischemia-reperfusion injury. (A) AST: Aspartate Aminotransferase; (B) ALT: Alanine Aminotransferase; (C) ALP: Alkaline Phosphatase; (D) Bili.T: Bilirubin Total. Data expressed as mean  $\pm$  SD. \* $P < 0.05$ , \*\* $P < 0.01$ , and \*\*\* $P < 0.001$  respectively compared to the Sham group. # $P < 0.05$ , ## $P < 0.01$  and ### $P < 0.001$  compared to the Ischemia group.

Moreover, the administration of ZnO NPs in both the IR+ZnO5 and IR+ZnO10 groups significantly attenuated the ALP levels to 636.60 (U/L) ( $P = 0.01$ ) and 588.33 (U/L) with

( $P < 0.01$ ) respectively in comparison to the IR group (Fig. 2C). ALP levels were significantly higher in the IR+ZnO5 group than in the IR+ZnO10 group ( $P = 0.01$ ) (Fig. 2C). The

T.Bili levels markedly decreased in the IR+ZnO5 and IR+ZnO10 groups compared with that in the IR group ( $P < 0.01$  in both groups) (Fig. 2D).

#### ***ZnO5 and ZnO10 attenuate the level of oxidant and inflammatory mediators in liver IR injury rats.***

To investigate the impact of IR liver injury on antioxidant status and inflammatory cytokine levels, we measured the levels of total antioxidant capacity (TAC), MDA, and TNF- $\alpha$ .

The results of this study showed a significant increase in TNF- $\alpha$  levels ( $P = 0$ ) following IR liver injury, which was mitigated by ZnO NPs (Fig. 3A). Both nano-ZnO5 and nano-ZnO10 markedly attenuated TNF- $\alpha$  levels in IR+ZnO5 and IR+ZnO10 groups compared to the IR group ( $P = 0$  for both) (Fig. 3A); however, nano-ZnO at higher dose (ZnO10) had better effect than ZnO5 to reduce TNF- $\alpha$  levels ( $P = 0.01$ ).

MDA levels in the IR group were significantly higher than those in sham rats ( $P = 0$ ) (Fig. 2). IR+ZnO5 and IR+ZnO10 administration reduced the level of MDA significantly compared to the IR group ( $P = 0.03$  and  $P = 0$ , respectively) (Fig. 3B). IR+ZnO10 significantly decreased MDA levels compared with the ZnO5 group ( $P < 0.01$ ).

In addition, TAC was declined significantly in the IR group compared to the sham group ( $P = 0$ ). IR+ZnO5 and IR+ZnO10 administration significantly elevated the TAC levels compared to the IR group ( $P = 0.03$  and  $P < .01$  respectively) (Fig. 2). Interestingly, ZnO10 administration elevated TAC levels to those in the sham group, and the results were significant compared to the IR+ZnO5 group ( $P = 0.02$ ) (Fig. 3C).

#### ***ZnO5 and ZnO10 decline apoptosis***

To examine the effect of ZnO5 and ZnO10 on apoptotic genes, the mRNA levels of caspase3, Bcl-2-associated X protein (BAX), and B-cell lymphoma 2 (Bcl2) were measured using RT-PCR. The results of RT-PCR revealed that the mRNA level of BAX was higher in the IR group than in the sham group ( $P = 0$ ) (Fig. 3D). Bcl2 expression level was notably lower in the IR group compared with the sham group ( $P = 0$ )

(Fig. 3E). ZnO5 and ZnO10 treatment markedly attenuated the mRNA level of BAX in comparison to the IR group ( $P = 0$  and  $p$ -value  $< 0.01$  respectively) (Fig. 3D). In contrast, Bcl2 was upregulated in the IR+ZnO5 and IR+ZnO10 groups when compared with IR group ( $P = 0.04$  and  $P = 0$  respectively). Statistical analysis showed that Bcl2 levels in the IR+ZnO10 group were significantly elevated compared with those in the IR+ZnO5 group ( $P = 0.01$ ) (Fig. 3E).

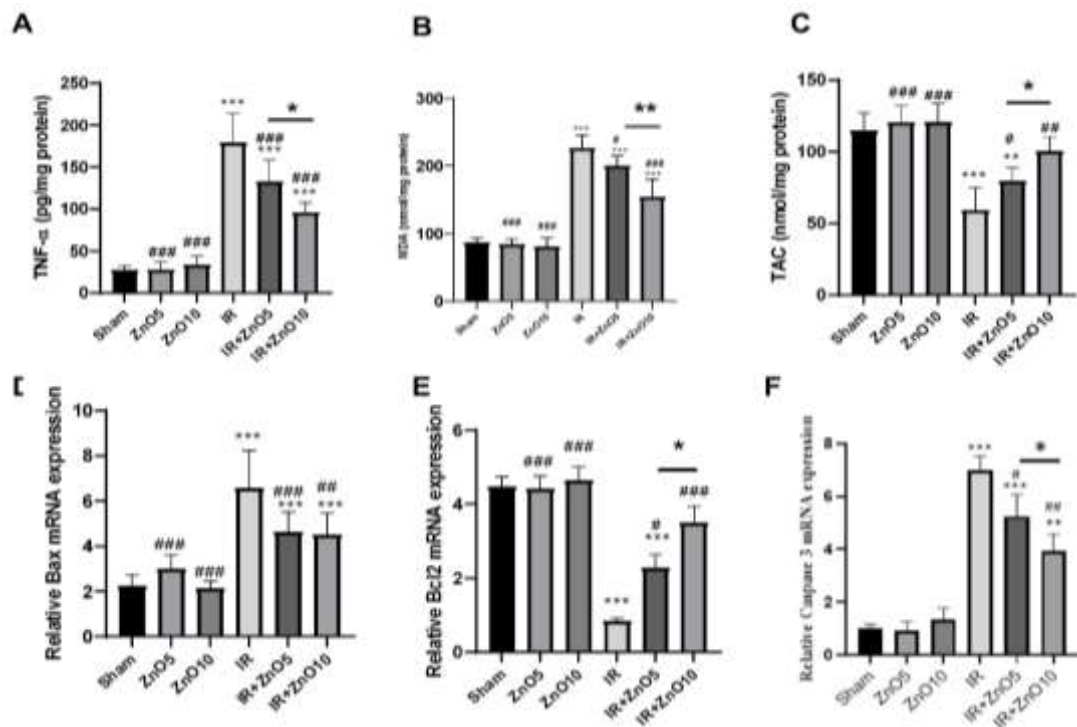
The mRNA level of caspase 3 was obviously upregulated in the IR group compared to the sham group ( $P > 0.001$ ) and ZnO NPs treatment contributed to the amelioration of apoptosis in a dose-dependent manner. As shown, the IR+ZnO10 group had a higher ameliorative effect than the IR+ZnO5 group ( $P = 0.02$ ) (Fig. 3F).

Histopathological examination of the hepatic lobules using Hematoxylin and Eosin staining revealed distinct differences between the sham, IR, and IR+ZnO5/IR+ZnO10 groups. The sham group exhibited a normal histological structure, while the IR group showed significant alterations, including a large area of necrosis and hemorrhage (yellow asterisk), centrilobular coagulative necrosis of hepatocytes with nuclear pyknosis (yellow arrow), and karyolysis (red arrow) scattered between the hepatic cords. However, in the IR+ZnO5 and IR+ZnO10 groups, the alterations decreased in a dose-dependent manner. Specifically, the areas of necrosis and hemorrhage were reduced, and centrilobular coagulative necrosis of hepatocytes with nuclear pyknosis and karyolysis was less frequent.

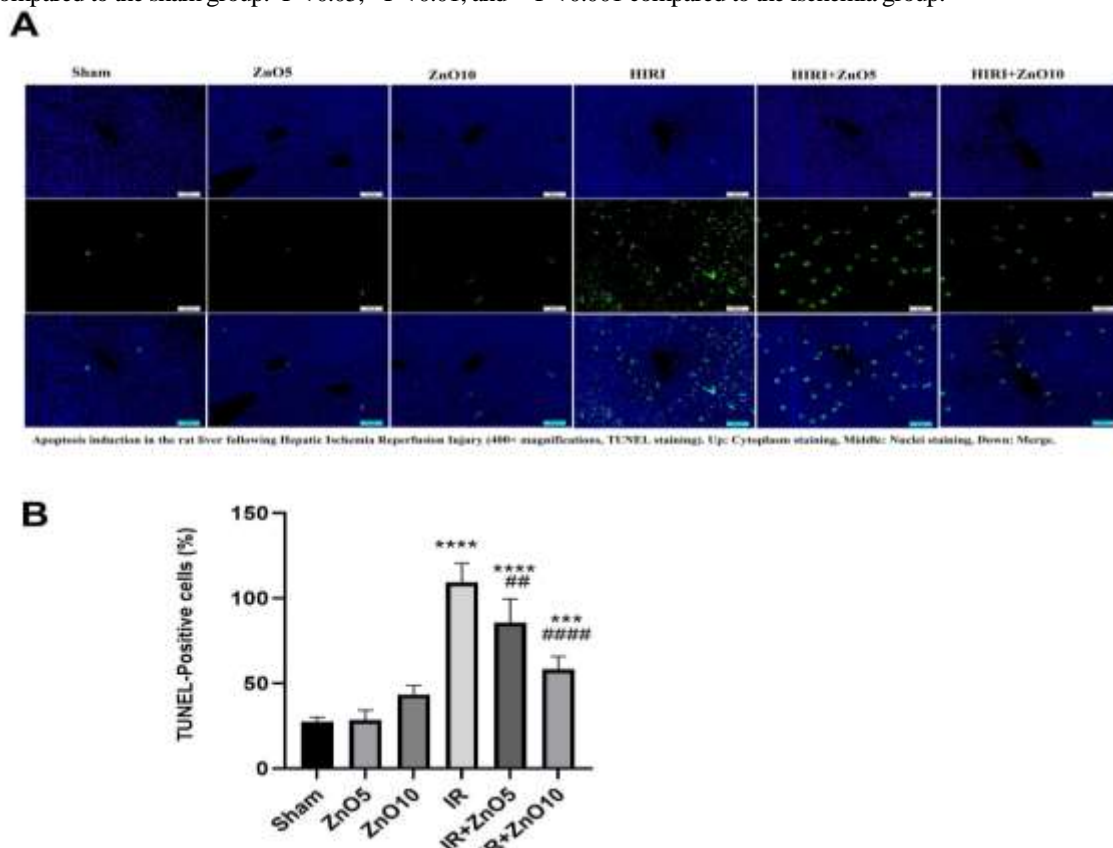
TUNEL staining revealed a significant increase in apoptosis in the liver tissue of rats subjected to ischemia-reperfusion injury. According to the representative images and cell count results, the occurrence of cell death through apoptosis was higher in the ischemia group than in the sham group, as indicated by the presence of TUNEL-positive cells ( $P = 0$ ). However, administration of IR+ZnO5 and IR+ZnO10 decreased the number of TUNEL-positive cells to 85.67% and 58.20%, respectively, (Fig. 4).



## ZnO Nanoparticles in Liver Ischemia-Reperfusion



**Fig. 3.** Administration of IR+ZnO5, and IR+ZnO10 attenuated the level of TNF- $\alpha$  and MDA in rats underwent ischemia-reperfusion comparing to the sham group. (A) TNF- $\alpha$ ; (B) MDA; (C) TAC (total antioxidant capacity). (D, E and F) mRNA expressions of BAX, Bcl2 and Caspase 3 in rats underwent liver ischemia-reperfusion injury. Data expressed as mean  $\pm$  SD. \*P<0.05, \*\*P<0.01 and \*\*\*P<0.001 compared to the sham group. #P<0.05, ##P<0.01, and ###P<0.001 compared to the ischemia group.



**Fig. 4.** ZnO NPs reduced the number of apoptotic cells in the rat liver following hepatic ischemia-reperfusion injury. A: TUNEL staining (400 $\times$  magnifications.). Top: Cytoplasm staining, Middle: Nuclei staining, Bottom: Merge. B: Percent of TUNEL positive cells.

## Discussion

The potential protective effects of ZnO5 and ZnO10 against liver ischemia-reperfusion injury are supported by a thorough analysis of liver function, inflammation, oxidative stress, apoptosis, and histological alterations. Our study demonstrated that low doses of nanoparticles significantly improved liver ischemic tissue. Administration of ZnO5 and ZnO10 improved liver function after ischemia-reperfusion injury, as evidenced by decreased serum levels of ALT, AST, T.Bili, and ALP and reduced apoptosis. These findings are consistent with previous studies demonstrating the beneficial effects of zinc on liver function in various liver injury models (10, 21, 22). In addition to improving hepatic function, ZnO5 and ZnO10 also demonstrated potential anti-inflammatory and antioxidant effects in the liver, as indicated by the significant reduction in MDA, TNF- $\alpha$ , and IL-6 levels. These results suggest that ZnO5 and ZnO10 may have anti-inflammatory and antioxidant effects in the liver, which may contribute to their protective effects against IR injury.

Reactive oxygen species (ROS) generation induces TNF- $\alpha$  synthesis, which is one of the most important primary cytokines (23). TNF- $\alpha$  production increases several minutes after the reperfusion phase, leading to the spread of oxidative stress and development of parenchymal damage and inflammatory responses (24). ZnO NPs may improve liver function in IR + ZnO NPs treated rats by inhibiting ROS production. In the present study, pretreatment with ZnO NPs increased TAC and inhibited lipid peroxidation. The decline in oxidative stress leads to a lower production of cytokines, such as TNF- $\alpha$ . Moreover, TNF- $\alpha$  exacerbates oxidative stress-induced damage and triggers apoptosis in liver cells (21, 25), potentially leading to necrosis or apoptosis of these cells, depending on the extent of damage (23).

The rate of apoptosis induced by liver ischemia varies depending on the severity and duration of the ischemia (26). Ischemia can cause a range of histological effects in the

liver, depending on the severity and duration of ischemia (27). During ischemia, liver cells are deprived of oxygen and nutrients, which can lead to cell death and tissue damage (28). The histological effects of ischemia include cellular swelling, vacuolization, and necrosis (29). Zinc has been shown to have a protective effect against histological alterations caused by ischemia in the liver (30).

Several studies have investigated the role of zinc in reducing apoptosis induced by liver ischemia (10, 12, 21). Overall, these studies suggest that zinc supplementation may be a promising approach to reduce apoptosis induced by liver ischemia. The ratio of BCL2 to BAX gene expression is a regulatory index that determines whether a cell will survive or undergo apoptosis, because it reflects the balance between these two factors in cells (31, 32). Our study showed that ZnO5 and ZnO10 treatment reduced apoptosis in the liver, as evidenced by the decreased mRNA levels of BAX and increased mRNA levels of BCL2. These results indicated that ZnO5 and ZnO10 may exert anti-apoptotic effects in the liver, potentially contributing to their protective properties against IR injury. In line with the improved histological signs of liver apoptosis, the liver caspase 3 mRNA level was also found to be significantly decreased by 5 and 10 mg/kg ZnO NP treatment. These findings suggest that treatment with 5 and especially 10 mg/kg ZnO-NPs could markedly attenuate apoptosis in the ischemic liver.

Zinc nanoparticles have been found to possess both toxic and protective effect (33). While zinc has been utilized as a toxic agent in creating experimental animal models in various studies (34-36), its potential beneficial effects, including antioxidant and anti-inflammatory properties, have also been reported (37, 38). However, the effect of these nanoparticles on ischemia-reperfusion liver injury has not been thoroughly investigated. Moreover, the influence of zinc nanoparticles on apoptotic genes expression and histological assessment of apoptosis in liver injury remains



unexplored. Consequently, extensive research is warranted to establish the safety and efficacy of zinc nanoparticles as therapeutic supplements. The clinical application of zinc nanoparticles raises uncertainties regarding their dosage and method of administration. Various studies have indicated that systemic administration has a greater potential for toxicity than oral administration (14, 39). However, it's important to note that the toxicity of ZnO NPs is influenced by various factors, including the particle size, surface characteristics, dose, and duration of exposure, in addition to the administration method (14, 40). Each administration method has its own set of considerations and potential toxicological implications, and the specific toxicity profile may vary depending on the intended target organ or system (13). Our study demonstrated that low doses of nanoparticles significantly improved liver ischemic tissue.

Nevertheless, further investigations into their effects on different tissues and inflammatory conditions are essential to determine the optimal dosage and administration protocols for these nanoparticles. Understanding the toxicological profile of higher doses is essential for evaluating the safety and efficacy of zinc oxide nanoparticles as a therapeutic intervention.

Additional studies are required to elucidate the specific pathways and signaling mechanisms through which zinc nanoparticles exert their protective effects against liver ischemia-reperfusion injury. In addition, this study highlights the necessity for determining the optimal dosage and timing of zinc supplementation for maximal efficacy in protecting against ischemia-reperfusion injury.

### References

1. Konishi T, Lentsch AB. Hepatic ischemia/reperfusion: mechanisms of tissue injury, repair, and regeneration. *Gene Expr.* 2017;17(4): 277-287.
2. Mao B, Yuan W, Wu F, Yan Y, Wang B. Autophagy in hepatic ischemia-reperfusion injury. *Cell Death Discov.* 2023;9(1):115.

Further investigations are warranted to establish the most effective administration protocol for ZnO NPs in the context of liver injury. These limitations indicate the need for additional research to address the gaps in understanding the precise mechanisms, optimal administration protocols, and specific role of metallothionein induction in the context of zinc nanoparticle-mediated protection against liver ischemia-reperfusion injury.

Our results suggest that ZnO5 and ZnO10 may have potential therapeutic applications in the treatment of IR-induced liver injury. However, the current study has some limitations. We did not explore other potential ZnO NPs-related mechanisms to ameliorate hepatic IR or verify the probability of the toxic effects of these compounds at higher dosages. Therefore, further studies are needed to fully elucidate the mechanisms underlying the protective effects of ZnO5 and ZnO10 in the liver and to determine the optimal dosage and timing of zinc supplementation for the treatment of liver injury.

### Conflict of Interest

The authors declare that they have no competing interests.

### Funding

This work was funded by the Research Affairs of Shoushtar Faculty of Medical Sciences, Shoushtar, Iran (400000001).

### Acknowledgments

We acknowledge the Research Affairs of Shoushtar Faculty of Medical Sciences, Shoushtar, Iran.

3. El-Bahy AA, Kassem LA, Heikal OA, Mahran LG. Antiapoptotic effect of DDB against hepatic ischemia-reperfusion injury. *J Toxicol Sci.* 2011;36(2):145-54.
4. Quesnelle KM, Bystrom PV, Toledo-Pereyra LH. Molecular responses to ischemia and reperfusion in the liver. *Arch Toxicol.* 2015;89:651-7.

5. Hofmann J, Pühringer M, Steinkellner S, Holl A-S, Meszaros AT, Schneeberger S, et al. Novel, Innovative Models to Study Ischemia/Reperfusion-Related Redox Damage in Organ Transplantation. *Antioxidants*. 2023;12(1):31.
6. Kalogeris T, Baines CP, Krenz M, Korthuis RJ. Cell biology of ischemia/reperfusion injury. *Int Rev Cell Mol Biol*. 2012;298:229-317.
7. Cannistrà M, Ruggiero M, Zullo A, Gallelli G, Serafini S, Maria M, et al. Hepatic ischemia reperfusion injury: A systematic review of literature and the role of current drugs and biomarkers. *Int J Surg*. 2016;33:S57-S70.
8. Elmorshdy Elsaed Mohammed Elmorshdy S, Ahmed Shaker G, Helmy Eldken Z, Abdelbadie Salem M, Awadalla A, Mahmoud Abdel Shakour H, et al. Impact of Cerium Oxide Nanoparticles on Metabolic, Apoptotic, Autophagic and Antioxidant Changes in Doxorubicin-Induced Cardiomyopathy: Possible Underlying Mechanisms. *Rep Biochem Mol Biol*. 2023;12(3):495-511.
9. Souri F, Badavi M, Dianat M, Mard SA, Sarkaki A. Effect of Gallic Acid Pretreatment and SGK1 Enzyme Inhibition on Cardiac Function and Inflammation in a Rat Model of Ischemia-Reperfusion Injury. *Rep Biochem Mol Biol*. 2023;12(1):159-72.
10. Dogra S, Kar AK, Girdhar K, Daniel PV, Chatterjee S, Choubey A, et al. Zinc oxide nanoparticles attenuate hepatic steatosis development in high-fat-diet fed mice through activated AMPK signaling axis. *Nanomedicine*. 2019;17:210-22.
11. Kim MH. Biological effects of zinc oxide nanoparticles on inflammation. *Cellmed*. 2016;6(4):23.1-6.
12. El-Bahr SM, Shousha S, Albokhadaim I, Shehab A, Khattab W, Ahmed-Farid O, et al. Impact of dietary zinc oxide nanoparticles on selected serum biomarkers, lipid peroxidation and tissue gene expression of antioxidant enzymes and cytokines in Japanese quail. *BMC Vet Res*. 2020;16(1):349.
13. Czyżowska A, Barbasz A. A review: zinc oxide nanoparticles – friends or enemies? *Int J Environ Health Res*. 2022;32(4):885-901.
14. Nagar V, Singh T, Tiwari Y, Aseri V, Pandit PP, Chopade RL, et al. ZnO Nanoparticles: Exposure, toxicity mechanism and assessment. *Mater Today Proc*. 2022;69:56-63.
15. Mohseni Kouchesfahani H, Ostadbagher Kashi A. The protective effect of ZnO nanoparticles on liver and impairments induced by paclitaxel treatment in female Wistar rat. *Nova Biologica Reperta*. 2016;3(3):218-27.
16. Torabi F, Malekzadeh Shafaroudi M, Rezaei N. Combined protective effect of zinc oxide nanoparticles and melatonin on cyclophosphamide-induced toxicity in testicular histology and sperm parameters in adult Wistar rats. *Int J Reprod Biomed*. 2017;15(7):403-12.
17. Abbasi-Oshaghi E, Mirzaei F, Mirzaei A. Effects of ZnO nanoparticles on intestinal function and structure in normal/high fat diet-fed rats and Caco-2 cells. *Nanomedicine*. 2018;13(21):2791-816.
18. Wahab R, Ansari SG, Kim YS, Dar MA, Shin H-S. Synthesis and characterization of hydrozincite and its conversion into zinc oxide nanoparticles. *J Alloys Compd*. 2008;461(1):66-71.
19. Jafar Sameri M, Belali R, Neisi N, Noei Razliqi R, Mard SA, Savari F, Azandeh SS. Sodium Hydrosulfide Modification of Mesenchymal Stem Cell-Exosomes Improves Liver Function in CCL4-Induced Hepatic Injury in Mice. *Rep Biochem Mol Biol*. 2023;11(4):644-655.
20. Sameri MJ, Savari F, Hoseinynejad K, Danyaei A, Mard SA. The hepato-protective effect of H<sub>2</sub>S-modified and non-modified mesenchymal stem cell exosomes on liver ischemia-reperfusion injury in mice: The role of MALAT1. *Biochem Biophys Res Commun*. 2022;635:194-202.
21. Rani V, Verma Y, Rana K, Rana SVS. Zinc oxide nanoparticles inhibit dimethylnitrosamine induced liver injury in rat. *Chem Biol Interact*. 2018;295:84-92.

22. Roma K, Mohammed S, Sieck B, Naik K, Wahid S. Kratom-induced acute liver injury: A case study and the importance of herbal supplement regulation. *J Hepatol.* 2023;79(2):581-584.
23. Meng X, Tang GY, Liu PH, Zhao CJ, Liu Q, Li HB. Antioxidant activity and hepatoprotective effect of 10 medicinal herbs on CCl<sub>4</sub>-induced liver injury in mice. *World J Gastroenterol.* 2020;26(37):5629-5645.
24. Li S, Qin Q, Luo D, Pan W, Wei Y, Xu Y, et al. Hesperidin ameliorates liver ischemia/reperfusion injury via activation of the Akt pathway. *Mol Med Rep.* 2020;22(6):4519-4530.
25. Sameri MJ, Savari F, Hoseinynejad K, Danyaei A, Mard SA. The hepato-protective effect of H<sub>2</sub>S-modified and non-modified mesenchymal stem cell exosomes on liver ischemia-reperfusion injury in mice: The role of MALAT1. *Biochem Biophys Res Commun.* 2022;635:194-202.
26. Liu Y, Lu T, Zhang C, Xu J, Xue Z, Busuttill RW, et al. Activation of YAP attenuates hepatic damage and fibrosis in liver ischemia-reperfusion injury. *J Hepatol.* 2019;71(4):719-730.
27. Czigany Z, Lurje I, Schmelzle M, Schöning W, Öllinger R, Raschok N, et al. Ischemia-Reperfusion Injury in Marginal Liver Grafts and the Role of Hypothermic Machine Perfusion: Molecular Mechanisms and Clinical Implications. *J Clin Med.* 2020;9(3):846.
28. Jiménez-Castro MB, Cornide-Petronio ME, Gracia-Sancho J, Peralta C. Inflammation-Mediated Inflammation in Liver Ischemia-Reperfusion Injury. *Cells.* 2019;8(10):1131.
29. Ye J, Peng J, Liu K, Zhang T, Huang W. MCTR1 inhibits ferroptosis by promoting NRF2 expression to attenuate hepatic ischemia-reperfusion injury. *Am J Physiol Gastrointest Liver Physiol.* 2022;323(3):G283-G293.
30. Akbari G. Role of Zinc Supplementation on Ischemia/Reperfusion Injury in Various Organs. *Biol Trace Elem Res.* 2020;196(1):1-9.
31. Chen Q, Liu Y, Ding X, Li Q, Qiu F, Wang M, et al. Bone marrow mesenchymal stem cell-secreted exosomes carrying microRNA-125b protect against myocardial ischemia reperfusion injury via targeting SIRT7. *Mol Cell Biochem.* 2020;465(1-2):103-114.
32. Korshunova AY, Blagonravov ML, Neborak EV, Syatkin SP, Sklifasovskaya AP, Semyatov SM, Agostinelli E. BCL2-regulated apoptotic process in myocardial ischemia-reperfusion injury. *Int J Mol Med.* 2021;47(1):23-36.
33. Elshama SS, Abdallah ME, Abdel-Karim RI. Zinc oxide nanoparticles: therapeutic benefits and toxicological hazards. *Open Nanomed J.* 2018;5(1):16-22.
34. Zhang Y, Zhang L, Mao L, Fan J, Jiang X, Li N, et al. Intestinal Microbiota-derived Propionic Acid Protects against Zinc Oxide Nanoparticle-induced Lung Injury. *Am J Respir Cell Mol Biol.* 2022;67(6):680-694.
35. Pei X, Jiang H, Li C, Li D, Tang S. Oxidative stress-related canonical pyroptosis pathway, as a target of liver toxicity triggered by zinc oxide nanoparticles. *J Hazard Mater.* 2023;442:130039.
36. Guo T, Fang X, Liu Y, Ruan Y, Hu Y, Wang X, et al. Acute lung inflammation induced by zinc oxide nanoparticles: Evolution and intervention via NRF2 activator. *Food Chem Toxicol.* 2022;162:112898.
37. Kaur T, Bala M, Kumar G, Vyas A. Biosynthesis of zinc oxide nanoparticles via endophyte *Trichoderma viride* and evaluation of their antimicrobial and antioxidant properties. *Arch Microbiol.* 2022;204(10):620.
38. Dkhil MA, Al-Quraishy S, Wahab R. Anticoccidial and antioxidant activities of zinc oxide nanoparticles on *Eimeria papillata*-induced infection in the jejunum. *Int J Nanomedicine.* 2015;10:1961-8.
39. Virgen-Ortiz A, Apolinar-Iribe A, Díaz-Reval I, Parra-Delgado H, Limón-Miranda S, Sánchez-Pastor EA, et al, Rodríguez-Hernández A. Zinc Oxide Nanoparticles Induce an Adverse Effect on Blood Glucose Levels Depending on the Dose and Route of Administration in Healthy and Diabetic Rats. *Nanomaterials.* 2020;10(10):2005.

40. Fujihara J, Nishimoto N. Review of Zinc Oxide Nanoparticles: Toxicokinetics, Tissue Distribution for Various Exposure Routes, Toxicological

Effects, Toxicity Mechanism in Mammals, and an Approach for Toxicity Reduction. *Biol Trace Elem Res.* 2024;202(1):9-23.